CNS 2017 ANNUAL MEETING
BOSTON, MASSACHUSETTS
OCTOBER 7–11, 2017

Steinmann Pins for C1 Lateral Mass Screw Placement in Atlantoaxial Stabilization

Joshua Meyers MD; Kunal Vakharia MD; John Pollina MD; Vassilios Georgios Dimopoulos MD
University at Buffalo Neurosurgery

Introduction

Multiple methods for C1-2 arthrodesis have been described. The use of a polyaxial screw and rod construct was popularized by Harms and Melcher in 2001. However, the placement of C1 lateral mass screws increases the risk of venous blood loss and injury to the C2 nerve root. The authors describe a technique for placement of C1 lateral mass screws using a Steinmann pin as a guide. The drill is inserted over the pins with a smooth protected guide canula over the drill bit minimizing dissection and providing atlantoaxial stabilization during arthrodesis.

Methods

In our technique, a non-threaded 1.6mm spade-tip Steinmann pin is placed into the lateral mass of C1 to serve as a guide over which a powered drill is used for screw insertion. Perioperative data were collected for 93 consecutive patients who underwent a C1-2 arthrodesis that involved the modified technique between March 2010 and July 2016. Data included blood loss, operative times, and C2 nerve root injury.

Results

The data for 93 patients were reviewed. Most (91.4%) patients presented with a fracture from an acute trauma. A mean of 1.97 levels was fused in these patients with a mean blood loss of 76 ml and a mean operative time of 144 minutes. The overall morbidity and mortality rate was 10.7%. The morbidity rate of 7.5% included 30 day postoperative respiratory failure and dysphasia. There were no postoperative vertebral artery injuries, hardware failures, or instances of occipital neuralgia.

Conclusions

The use of Steinmann pins to guide the placement of C1 lateral mass screws is safe and effective in C1-2 arthrodesis. Limiting dissection minimizes blood loss and injury, maintains efficient operative time, and assists in accurate placement of the screws. With less manipulation and retraction of the C2 nerve root, postoperative occipital neuralgia and the need for C2 root transection are avoided.

Learning Objectives

By the conclusion of this session, participants should be able to 1. Describe the method of C1 lateral mass screw placement using Steinmann pins. 2. Discuss the perioperative complications associated with its use 3. Discuss the intraoperative advantages including operative time, blood loss, and C2 root injury.

Placement of C1 Lateral Mass Screws Using Steinmann Pins

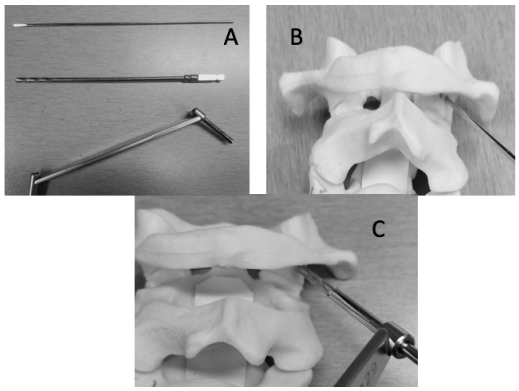

A. 1.6mm Steinmann pin with smooth spade tip (top), 2.9mm drill bit (middle), smooth guide cannula (bottom). B. Steinmann pin in place using a powered driver into the C1 lateral mass C. The drill bit and smooth cannula can be placed over the Steinmann pin flush with the lateral mass for accurate and safe drilling of the pilot hole.

References

1.Bourdillon P, Perrin G, Lucas F, Debarge R, Barrey C: C1-C2 stabilization by Harms arthrodesis: indications, technique, complications and outcomes in a prospective 26-case series. Orthop Traumatol Surg Res 100:221-227, 2014

2.Bransford RJ, Freeborn MA, Russo AJ, Nguyen QT, Lee MJ, Chapman JR, et al: Accuracy and complications associated with posterior C1 screw fixation techniques: a radiographic and clinical assessment. Spine J 12:231-238, 2012

3.Dewan MC, Godil SS, Mendenhall SK, Devin CJ, McGirt MJ: C2 nerve root transection during C1 lateral mass screw fixation: does it affect functionality and quality of life? Neurosurgery 74:475-480; discussion 480-471, 2014

4.Elliott RE, Tanweer O, Frempong-Boadu A, Smith ML: Impact of starting point and C2 nerve status on the safety and accuracy of C1 lateral mass screws: meta-analysis and review of the literature. J Spinal Disord Tech 28:171-185, 2015

5.Fiore AJ, Haid RW, Rodts GE, Subach BR, Mummaneni PV, Riedel CJ, et al: Atlantal lateral mass screws for posterior spinal reconstruction: technical note and case series. Neurosurg Focus 12:E5, 2002

6.Gautschi OP, Payer M, Corniola MV, Smoll NR, Schaller K, Tessitore E: Clinically relevant complications related to posterior atlanto-axial fixation in atlanto-axial instability and their management. Clin Neurol Neurosurg 123:131-135, 2014