

# Outcome of surgical versus conservative management of cervical spine myelopathy secondary to cervical tuberculosis

Ahmed Mohamed Elsawaf MD PhD



## Introduction

Cervical spine tuberculosis is a rare infectious disease that is not yet discussed well regarding the optimal method of its management

## Methods

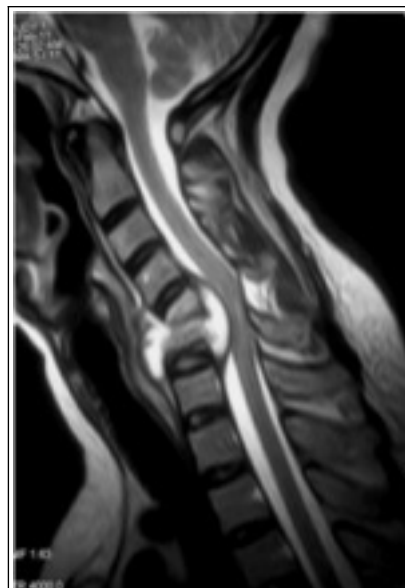A prospective study of a total of 29 patients with cervical spine tuberculosis with a mean follow-up of 14 months (range 10-21), they were classified randomly into two groups: Group I: Patients who underwent anterior cervical decompression and fixation and followed by the anti-tuberculous medications (16 patients). Group II: Patients who had conservative anti-tuberculous medications only without surgical intervention (13 patients). All patients had complete clinical assessments using Nurick scale and the modified Japanese Orthopaedic Association (mJOA) score for myelopathy and the visual analogue scale (VAS) for assessment of cervical pain. We had also neuro-radiographic assessment (cervical spine X-ray and MRI) at the first presentation and at 3, 6 and 12 months later

## Results

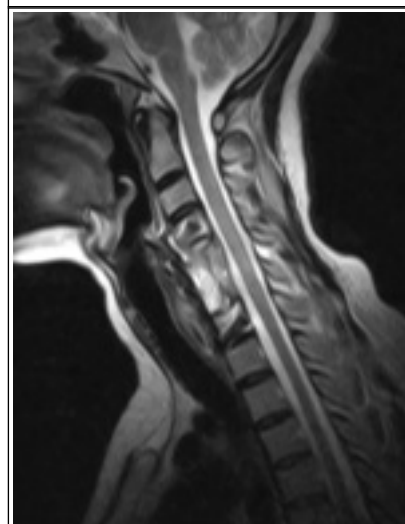
At final follow-up, significant neurological improvement was demonstrated in both management approaches, more obvious in the surgical group. Cervical pain showed statistically significant improvement ( $P < 0.05$ ) in surgical group rather than in conservatively-treated group. In the surgical group, the mean Cobb angle showed significant change from a preoperative mean of  $-3.1^\circ \pm 1.6$  to postoperative mean of  $16.6^\circ \pm 5.4$ , significantly correlated to the improvement of cervical pain ( $P = 0.004$ ), while it was changed from a mean  $-0.8 \pm 2.2$  to a mean of  $9.2 \pm 3.8$  one year after starting of medical treatment in group II

## Learning Objectives

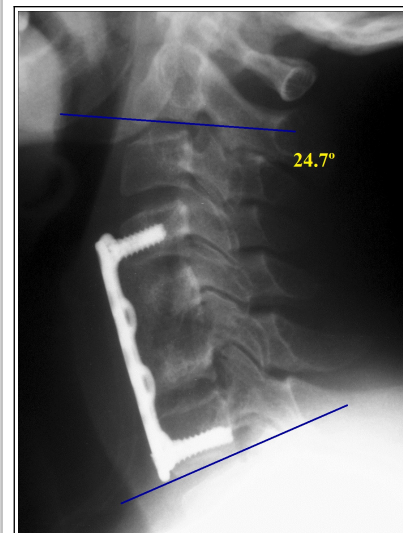
to know the best way for treatment of cervical spine tuberculosis



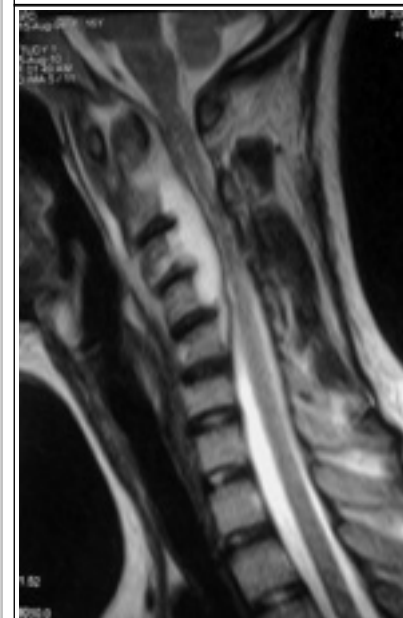
preoperative sagittal T2-WI MRI showed destruction of C5-C6 vertebral bodies with epidural collecting pus compressing the cord at that level



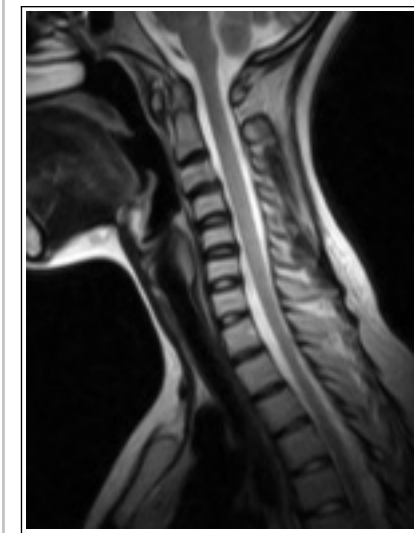Postoperative sagittal T2-WI MRI showed complete evacuation of the abscess and decompression of neural structures



Postoperative X-ray showed correction to a normal lordotic angle of  $25^\circ$  and good iliac crest autograft and fixation system



sagittal T2-WI MRI of a 22 years old female patient treated conservatively with medical treatment



sagittal T2-WI MRI at 1 year follow-up after medical treatment showing complete resolution of the epidural abscess with mild spastic kyphosis

## Conclusions

In spite of the conservative trend in the management of Pott's disease, surgical management of cervical spine myelopathy secondary to cervical tuberculosis could be the optimal treatment even in an early stage of the disease