

### Introduction

Despite its long reported successful record, with almost 60 years of clinical use, the technical complexity regarding the placement of stereo-electroencephalography (SEEG) depth electrodes might have contributed to the limited widespread application of the technique and methodology in centers outside Europe.

### Methods

Analyses included all patients with medically refractory focal epilepsy who underwent robotic stereotactic placement of depth electrodes for extra-operative brain monitoring using the SEEG method between November 2009 and May 2013. All the procedures were performed using the robotic assistant device ROSA<sup>®</sup>. (Medtech, Montpellier, France). Technical nuances regarding the robotic implantation technique are presented as well as analysis of demographics, time of planning and procedure, application accuracy, seizure outcome, in vitro and in vivo accuracy and procedure-related complications.

### Learning Objectives

To report the clinical experience with robotic SEEG implantation, defining its utility in the management of patients with medically refractory epilepsy who are candidates for extra-operative invasive monitoring using the SEEG methodology.

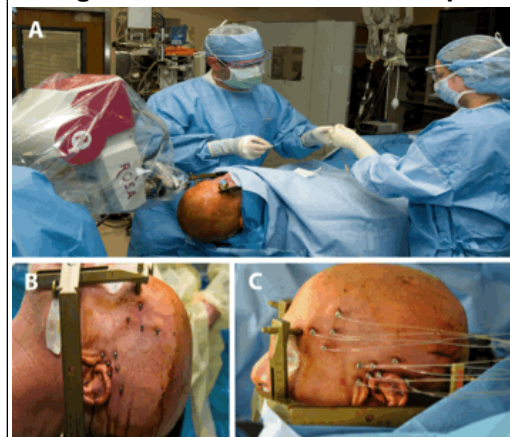### Conclusions

The robotic SEEG technique and method demonstrated to be safe, accurate and efficient in anatomically defining the epileptogenic zone and promoting seizure freedom status in patients with difficult to localize seizures. The findings from this study demonstrate its feasibility, translating into a modern and simplified alternative to the traditional SEEG technique, without compromising efficiency and safety.

### Results

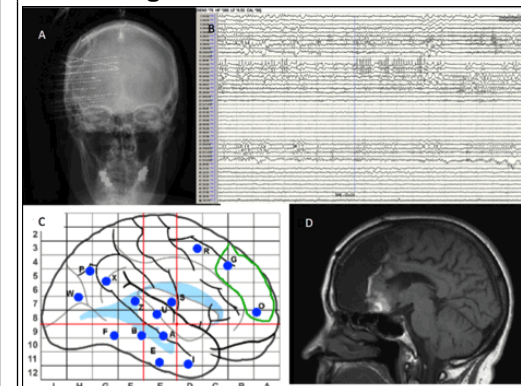
One hundred patients underwent 250 robotic-assisted SEEG procedures. The mean age was 33.2 years. In total, 1245 depth electrodes were implanted. On average, 12.5 electrodes were implanted per patient. All procedures were completed without cancellations due to hardware or software dysfunction. Time of planning was 30 minutes in average (ranging from 15 to 60 minutes). The average operative time was 130 minutes (range from 45 to 160 minutes). In vivo application accuracy, tested in 500 consecutive trajectories, demonstrated the mean entry point error of  $1.3 \pm 0.8\text{mm}$  (SD) and the mean target point error of  $2.3 \pm 0.9\text{mm}$  (SD). From the group of patients who underwent resective surgery (68 patients), 45 (66.2%) gained seizure freedom status. Mean follow-up was 18 months. Major complication rate was 1%.

**Figure 1. Robotic SEEG technique**



A: Operating room “set up” during left side SEEG robotic implantation, with surgeon and scrub nurse positioned on each side of the patient, and the robot device placed in the middle, at the vertex. B: Intraoperative aspect of left side frontal-temporal SEEG implantation with the guiding bolts final position. C: Left side frontal-temporal SEEG implantation after the depth electrodes implantations. Final aspect.

**Figure2: Illustrative case**



65 years old female patient with intractable epilepsy and non-lesional MRI. A: AP X ray showing right SEEG implantation. B: Interictal spikes from the right mesial frontal electrode. C: Ictal onset from right mesial frontal electrode (G) and Right fronto-polar electrode (O). D: Post operative MRI showing right frontal resection of G and O electrode regions as well as the non-sampled orbitofrontal region.