

# Occipital Nerve Stimulation for Intractable Occipital Neuralgia: An Open Surgical Technique

*Philippe Magown, M.D.C.M., René Garcia, M.D., Ian Beauprie, M.D.,  
and Ivar M. Mendez, M.D., Ph.D.*

Occipital neuralgia (ON) is defined as a paroxysmal jabbing pain in the cutaneous distribution of the greater or lesser occipital or third occipital nerve.<sup>10</sup> The pain is frequently described as sharp, shooting, stabbing or electrical, preferentially unilateral and remitting, radiating to the occipital and frontal areas, with associated symptoms suggesting a pain origin from the neck.<sup>2,3</sup> ON tends to become chronic and must be distinguished from referred pain to the occiput. Etiologies of occipital neuralgia include traumatic (72% of this series), degenerative (14% of this series), and oncological or idiopathic (14% of this series). Most cases arise from a flexion-extension injury to the neck (i.e., whiplash), which commonly results from a rear-end motor vehicle collision.<sup>8</sup> Treatment modalities for ON vary from conservative measures, which are usually the frontline treatments, to injections and surgical interventions. Injections such as regional anesthetic nerve block are initially effective in the majority of cases and are also helpful as a diagnostic tool.<sup>5,19,28</sup> More recently, botulinum toxin A injection has been used with varied results,<sup>4,14</sup> and a recent systematic review was equivocal because of the small number of patients.<sup>24</sup> Surgical approaches are indicated for medically intractable ON and are often considered as the last resort. Surgical modalities include decompressive, ablative, and stimulating procedures. The clinical efficacy of these procedures varies, and each has complications of its own. Electrical stimulation of the occipital nerve has been previously reported as a nonablative modality to treat ON.<sup>6,9,12,20–22,27</sup> The techniques described for stimulation of the occipital nerve use a fluoroscopic percutaneous approach to insert the stimulating electrode. However, this blind approach does not ensure that the electrode is directly in contact with the nerve trunk. The reported efficacy varies between 60% and 90% of pain relief<sup>21</sup> and can diminish substantially with malpositioning or migration of the electrode lead. It is known that percutaneous occipital electrodes are prone to migration with subsequent loss of stimulation and often need surgical revision,<sup>13</sup> even after meticulous anchorage techniques.<sup>7</sup> Migration rates are study dependent, ranging from

zero to 100%, with an average of approximately 15%; the readers are referred to a systematic review on implanted occipital nerve stimulators by Jasper et al.<sup>11</sup> for more details. We postulate that suboptimal positioning of the electrode in relation to the nerve trunk and migration of the percutaneously placed electrode in the highly mobile cervical region are the reasons for loss of stimulation. In an attempt to solve the problem of electrode positioning and migration, we developed an open surgical approach that allows visualizing the occipital nerve and ensures meticulous anchoring of the electrode onto the main trunk of the nerve.

## METHODS

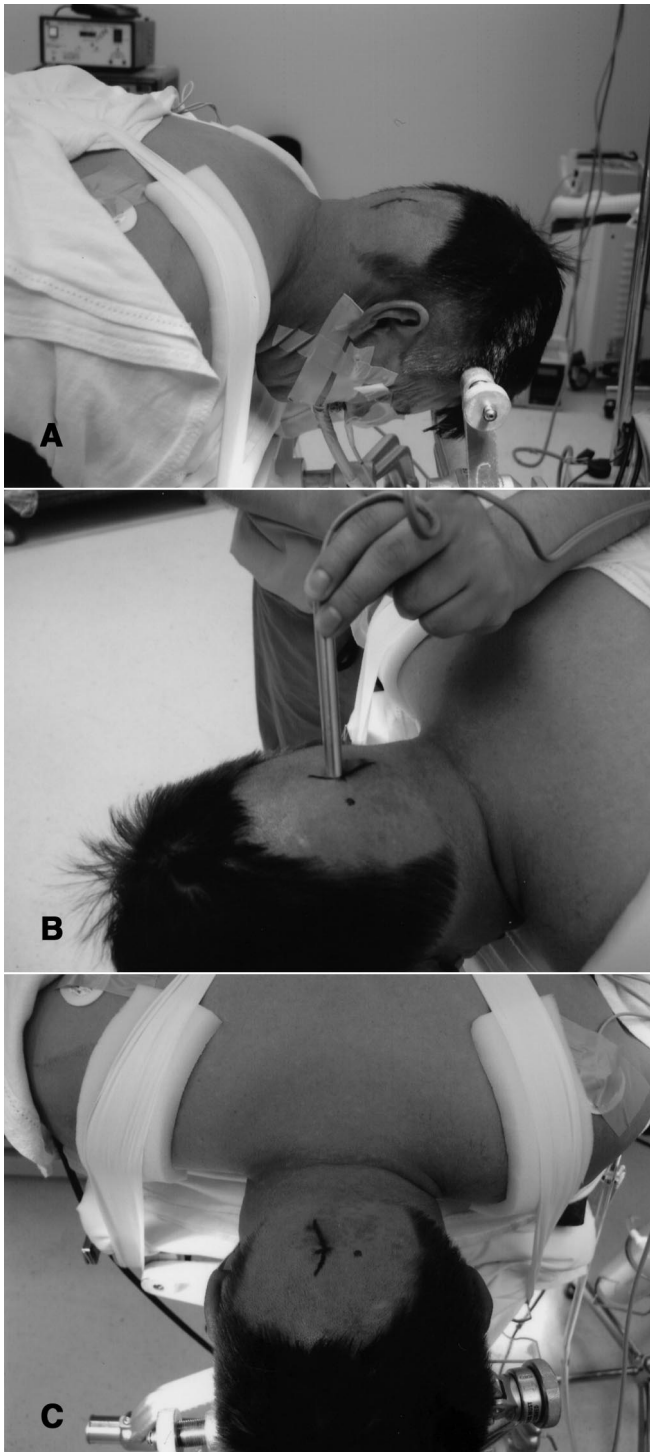
The Capital Health District Authority Ethic Committee approved this protocol.

### Patients

Patients fulfilling the diagnostic criteria for ON<sup>1,10,15,23</sup> in the greater occipital nerve distribution defined as paroxysmal stabbing pain, with or without persistent aching between paroxysms, associated with tenderness over the affected nerve were selected for a C2 nerve root double-blinded test of local anesthetic or saline injection. Those whose head pain was relieved by anesthetic blockade were confirmed to have ON<sup>19</sup> and were assessed for stimulator implantation. Patients were excluded based on the following criteria: previous surgery in the occipital region, medical conditions preventing general anesthesia, axis I disorders affecting pain perception, memory difficulties or dementia, or the inability to cooperate and give informed consent. Patients were assessed in our Pain Management Unit by a third party not connected to the study (expanded-role nurse) and were required to rate their pain on a Visual Analogue Scale (VAS). Medication consumption was also meticulously recorded. This research protocol was approved by the Queen Elizabeth II Hospital Ethics Committee.

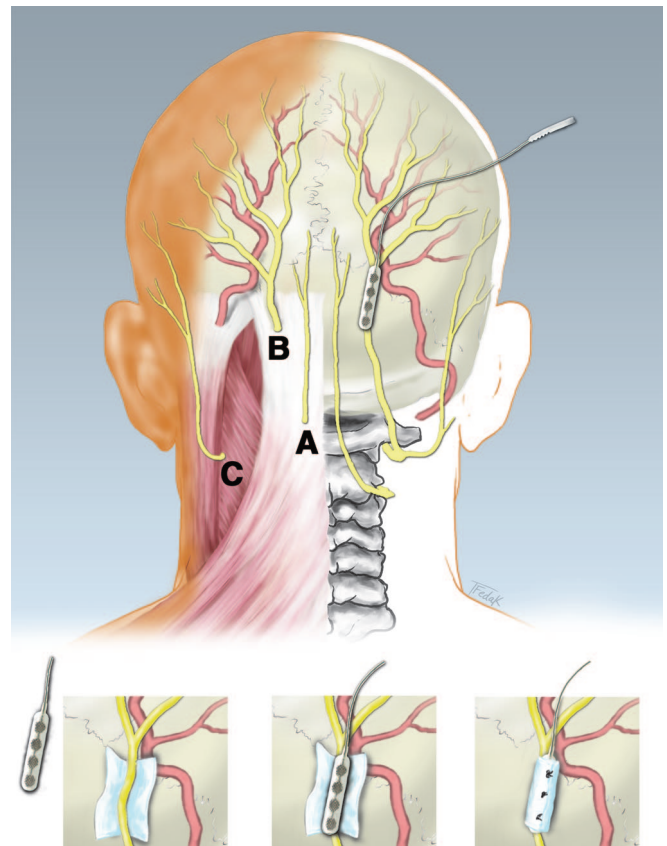
### Operative Technique

The surgery is performed with the patient under general anesthesia. The patient is positioned prone on the operating table with the head midline, slightly flexed in a Mayfield headholder (*Fig. 20.1A*). The hair over the occipital area is clipped and a

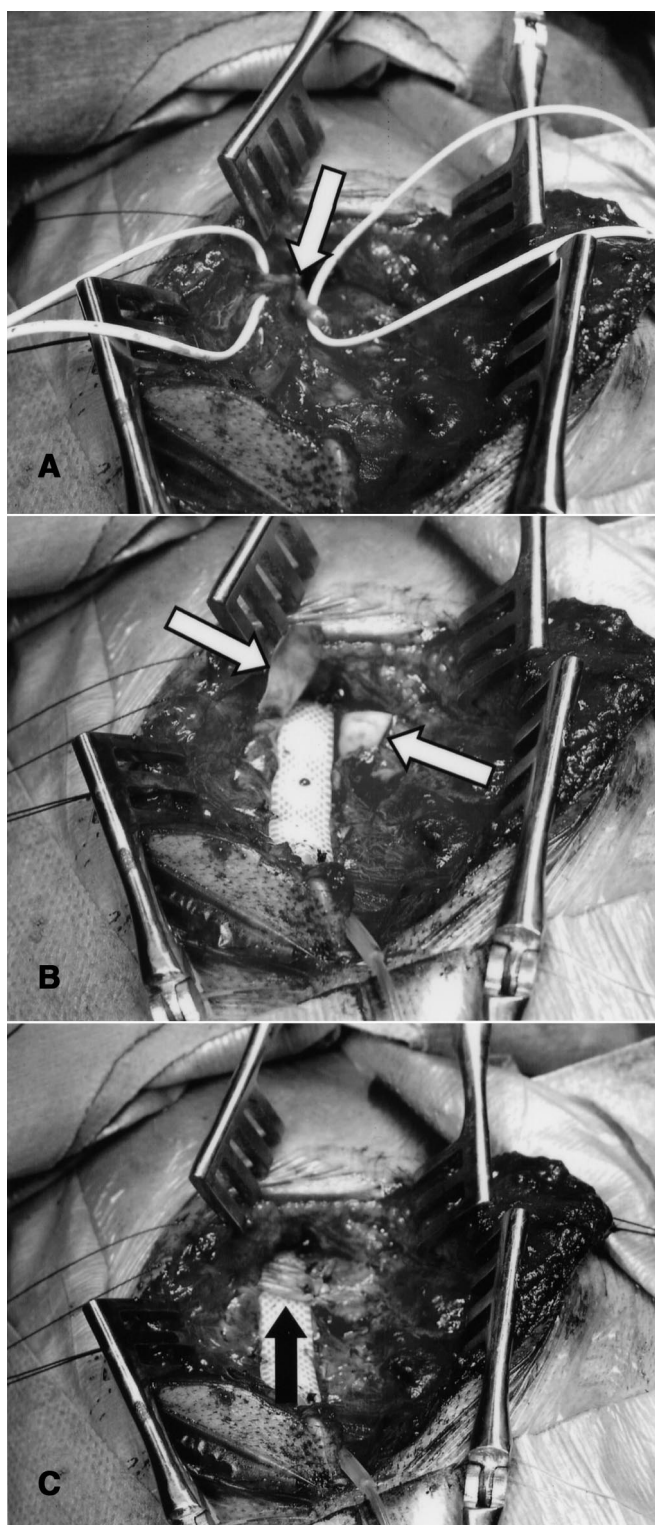


**FIGURE 20.1.** Surgical positioning. **A**, The patient is positioned prone with the head midline, slightly flexed and fixed in a Mayfield headholder. **B**, The Doppler probe is used to identify the occipital artery between the superior nuchal line and the posterior craniocervical junction. **C**, The course of occipital artery is used as a guide to mark the incision on the skin.

Doppler probe (Ultrasonic Doppler, Flow Detector Model 811-BTS; Parks Medical Electronics Inc., Aloha, OR) is used to identify the course of the occipital artery from the superior nuchal line to the posterior craniocervical junction (*Fig. 20.1B*). The skin incision is drawn over the course of the artery (*Fig. 20.1C*). This is a key step in identifying the occipital nerve as the artery follows an intimate parallel trajectory with the nerve. The surgical procedure is diagrammed step by step in *Figure 20.2*. The surgical dissection is performed under loupe magnification. After careful skin preparation and draping, a superficial incision through the skin and subcutaneous tissue is made with a scalpel. A small Weitlaner retractor is placed to spread carefully the skin incision; it is important to avoid sectioning the branches or the trunk of the occipital artery because it is used as a landmark to find the nerve. The occipital artery is followed proximally with sharp dissection to its origin, where just medial, a branch of the occipital nerve is usually identified. The branch is followed through the nuchal fascia until the main trunk of the nerve is visualized and can be exposed. The main trunk is skeletonized for at least 3 cm in length to slide a small cuff of bovine



**FIGURE 20.2.** Schematic representation of the open surgical technique step by step. Letters represent the following structures: third occipital nerve (**A**), greater occipital nerve (**B**), and lesser occipital nerve (**C**).

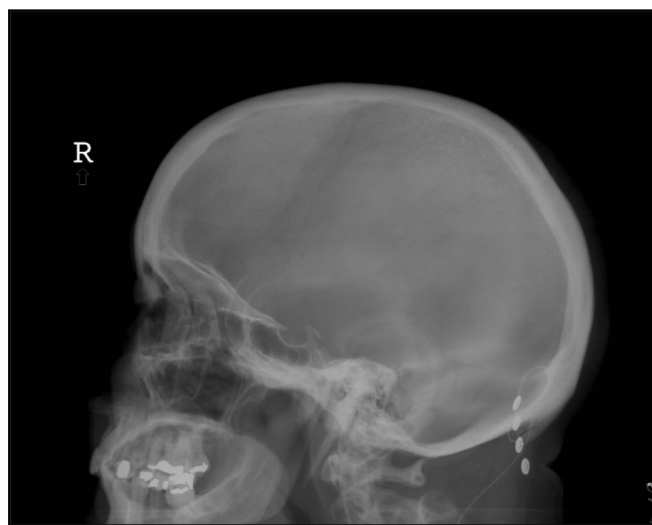


**FIGURE 20.3.** Intraoperative photographs. **A**, Dissection and preparation of the main trunk and branches of the occipital nerve (white arrow). **B**, A small cuff (white arrows) is placed underneath the occipital nerve to hold the Resume 2 electrode. **C**, The cuff (black arrow) is enfolded and sutured in.

pericardium underneath (Dura-Guard; Synovis Surgical Innovations, St. Paul, MN) (*Fig. 20.3A*) to hold the lead (Resume 2; Medtronic Sofamor Danek, Inc., Minneapolis, MN) in place. The lead is inserted upside down with its distal pole pointing toward the patient's shoulders such that the wire runs upward to the superior nuchal line (*Fig. 20.3B*). This prevents the trapezius muscle to pull down on the lead with each contraction. It also allows the wire to be run in the subcutaneous space without crossing a fascia plane. The cuff is loosely wrapped around the nerve and sutured to secure the lead (*Fig. 20.3C*). Care is taken as to not strangulate the nerve with the cuff. The area is irrigated copiously with saline and bacitracin solution, and the wound is temporarily closed. The patient is turned to a supine position, the Mayfield holder is removed, and the head is slightly rotated contralaterally to the occipital wound. The infraclavicular region and the occipital wound are prepared and draped. The occipital incision is reopened and the proximal end of the electrode is retrieved. A small subcutaneous pocket in the infraclavicular area is fashioned to house the pulse generator. The connecting cables are passed from the head to the chest area, and the electrode is connected to the subcutaneous pulse generator (Itriel III; Medtronic). Incisions are closed, and sterile dressings are applied. Skull x-ray to document baseline position of the lead (*Fig. 20.4*) is obtained postoperatively before the activation of the stimulator.

## RESULTS

Patient demographic data and the characteristics of the pain are shown in *Table 20.1*. There were five women and two men (mean [standard deviation] age, 44 [9] years). The etiology of ON was traumatic secondary to a motor vehicle accident in five cases (patients 1, 3, 4, 5, and 6). Patient two



**FIGURE 20.4.** Postoperative skull x-ray showing the position of the electrode.

TABLE 20.1. Demographic data and pain characteristics<sup>a</sup>

Patient	Age (y)	Sex	Etiology	Pain Descriptions	Cutaneous Distribution of Pain	Onset of Symptoms (y)	Follow-Up (mo)
1	44	F	MVC whiplash, migraine	Burning, searing	Greater occipital nerve	7	30
2	48	F	Idiopathic	Excruciating	Greater occipital nerve	10	28
3	50	M	MVC whiplash	Wrenching	Greater occipital nerve	11	24
4	45	M	MVC whiplash	Lancinating	Greater occipital nerve	4	20
5	40	F	MVC whiplash	Stabbing	Greater occipital nerve	6	17
6	27	F	MVC whiplash	Throbbing, aching	Greater occipital nerve	6	3
7	53	F	ACDF, CS	Unbearable, squeezing	Greater occipital nerve	9	2

<sup>a</sup>MVC, motor vehicle crash; ACDF, anterior discectomy and fusion; CS, cervical spondylosis.

TABLE 20.2. Parameters of stimulation

Patient	Last Follow-Up Parameters			
	Amp (V)	Pulse Width ( $\mu$ s)	Frequency (Hz)	Impedance ( $\Omega$ )
1	2.3	120	90	731
2	1.8	120	120	660
3	2.2	130	90	730
4	1.6	120	90	424
5	5.0	180	31	426
6	6.3	90	60	543
7	0.9	60	40	>4000

had idiopathic ON, whereas ON developed in patient seven after a C5–C6 anterior cervical discectomy and fusion and cervical spondylosis.

The mean follow-up was 17.7 months with a standard deviation of 11.3 months. The last follow-up stimulation parameters are shown in *Table 20.2*. The VAS was 100 mm in three patients and 72, 76, 80, and 90 mm in the other four patients before the operation. Postoperative VAS was 0 in all patients except in patient one, who had a 25-mm VAS postoperatively (*Table 20.3*). This patient had a 75% reduction of pain with intermittent stimulations. The cuff was not used in this first patient but was later instituted for all others. Overall, there was a mean reduction of experienced pain of 96% on the VAS.

A seroma over the lead incision with wound dehiscence and lead exposure developed in patient six. An attempt to save the lead and the stimulator was performed by incision and drainage of the wound. The lead was then buried underneath the aponeurosis to prevent further erosion through the skin. Antibiotic therapy was instituted for six weeks starting with vancomycin intravenously; vancomycin was changed mid-course to ciprofloxacin and rifampin because an allergic dermatitis developed in the patient. The lead was explanted after antibiotic failure.

All patients stopped pain medications with the exception of two: one of whom stopped intake of opioids and halved the amount of gabapentin from 2400 mg to 1200 mg daily; the other patient maintained the same regimen.

## DISCUSSION

We described a novel open surgical technique for stimulation of the occipital nerve in patients with intractable ON. This open technique is advantageous over the percutaneous procedure by ensuring visual identification of the main trunk of the occipital nerve allowing optimal positioning of the stimulating electrode. The sling cuff was instituted after the first patient who had intermittent stimulation because of intermittently losing contact with the electrode with movement of the neck. The secure apposition of the electrode to the nerve using a pericardial sling prevents loss of contact and displacement of the electrode and subsequent loss of stimulation. In fact, displacement of electrodes has been reported as the most serious complication of ON, often requiring surgical intervention.<sup>13,22,25</sup> A fluoroscopy-guided percutaneous technique is commonly used for stimulator insertion in intractable ON.<sup>27</sup> Although this percutaneous technique has shown beneficial effects on pain control in implanted patients, the blind nature of the electrode positioning has also resulted in surgical revision or explantation secondary to migration or malpositioning of the electrode lead.<sup>17,27</sup> Percutaneous approaches have been presented with migration rates of 10% to 70%, depending on the selected series.<sup>13,17,21,22,27</sup> Oh et al.<sup>17</sup> suggested inserting paddle electrodes percutaneously instead to provide greater stability and fixation with a larger electrode, there was no migration in seven previously revised patients. However, Magis et al.<sup>16</sup> reported just as much migration with paddle electrodes. The mechanism behind electrode migration is likely related to the highly mobile nature of the neck. Anchoring the electrode on the nerve using a pericardial sling can resolve this issue. The sling is not used as a constrictive sheath

TABLE 20.3. Outcomes<sup>a</sup>

Patient	VAS		Pain Relief (%)	Preop Pain Medications		Medications at Last Follow-up
	Preop	Postop		Therapeutic	Failed <sup>b</sup>	
1	100	25	75	Amitriptyline 40 mg q hs Tramacet 2 tablets tid prn Fiorinal 2 tablets prn for flare-up (3 times weekly) Marcaine 0.25% 5 mL ± Depo-Medrol 4-mg injection q 4 mo	Celebrex, Vioxx, Ibuprofen, Indomethacin Gabapentin Codeine, Morphine, Demerol Darvon-N	Ketoprofen 100 mg bid Methadone 25 mg/d Injection stopped
2	100	0	100	Effexor 37.5 mg bid Ibuprofen 400 mg or ASA 325–650 mg q6h Marcaine 0.25% 5–10 mL ± Depo-Medrol 60- to 80-mg injection q 3 mo	Nortriptyline, Desipramine Acetaminophen and Codeine Inderal LA	None Injection stopped
3	90	0	100	Effexor 225 mg/d ASA 325 mg qid prn Marcaine 0.25% 5 mL injection mo × 3	Amitriptyline Vioxx, Indomethacin Acetaminophen and Codeine Gabapentin, Topamax Codeine contin, MS Contin	None Injection stopped
4	80	0	100	Demerol 50 mg po q4h prn Marcaine 0.25% 5 mL ± Depo-Medrol 40-mg injection q 3 mo	Amitriptyline Acetaminophen and Codeine Gabapentin Botox A	None Injection stopped
5	100	0	100	Percocet 5 mg/325 mg q4h prn Marcaine 0.25% 5 mL ± Depo-Medrol 40-mg injection q 2 mo	N/A	None Injection stopped
6	72	0	100	Trazodone 50 mg q hs Naprosen 500 mg q12h Codeine contin 100 mg po bid Marcaine 0.25% 5–10 mL ± Depo-Medrol 40-mg injection q 3 mo	Arthrotec and Ibuprofen Tramadol Botox A	None Injection stopped
7	76	0	100	Acetaminophen 650 mg and codeine 60 mg tid, gabapentin 2400 mg/d Marcaine 0.5% 2 mL ± Depo-Medrol 40 mg injection q 4 mo	Amitriptyline, Desipramine Norflex, Flexeril	Gabapentin 1200 mg/d Injection stopped

<sup>a</sup>VAS, Visual Analogue Scale; Preop, preoperative; Postop, postoperative; q, every; hs, night; bid, twice daily; tid, 3 times daily; ASA, aspirin; prn, as needed; qid, 4 times daily; po, orally.

<sup>b</sup>Failure includes failed medications and medications stopped because of side effects or insufficient and sporadic effects.

around the nerve but as a loose envelop to prevent the electrode from moving away or rotating off the trajectory of the nerve.

In this initial experience, we found this open technique simple, safe, and effective in maintaining direct contact between the electrode and the nerve trunk. Importantly, this technique is performed in an anesthetized patient, eliminating patient motion during the implantation.

The first report of an open approach to implanting a nerve stimulator was published by Picaza et al.<sup>18</sup> in 1975. A subsequent report published by Waisbord et al.<sup>26</sup> in 1985 included one patient undergoing occipital nerve stimulator implantation using an open technique. However, the Avery stimulator required open insertion because of its substantial size. To our knowledge, no other report of an open surgical approach for insertion of occipital nerve stimulator is available in the literature.

## CONCLUSION

Although the number of patients in this study is relatively small and a longer follow-up is necessary, this open technique ensures optimal and secure placement of the stimulating electrode on the main trunk of the greater occipital nerve and may contribute to the surgical treatment of intractable ON.

## Acknowledgments

This article was presented as an open paper at the 2008 annual CNS meeting during the session on pain. The authors thank Ron Hill for his support with the photographs.

## Disclosure

Dr. Mendez has been a consultant for Medtronic. No financial contribution from Medtronic was provided for this project. The other authors have no personal financial or institutional interest in any of the drugs, materials, or devices described in this article.

## REFERENCES

1. Antonaci F, Ghirmai S, Bono G, Sandrini G, Nappi G: Cervicogenic headache: Evaluation of the original diagnostic criteria. **Cephalalgia** 21:573–583, 2001.
2. Becser N, Bovim G, Sjaastad O: Extracranial nerves in the posterior part of the head. Anatomic variations and their possible clinical significance. **Spine** 23:1435–1441, 1998.
3. Bogduk N: The anatomy of occipital neuralgia. **Clin Exp Neurol** 17:167–184, 1981.
4. Freund BJ, Schwartz M: Use of botulinum toxin in chronic whiplash-associated disorder. **Clin J Pain** 18:S163–S168, 2002.
5. Gawel MJ, Rothbart PJ: Occipital nerve block in the management of headache and cervical pain. **Cephalalgia** 12:9–13, 1992.
6. Goadsby PJ, Bartsch T, Dodick DW: Occipital nerve stimulation for headache: Mechanisms and efficacy. **Headache** 48:313–318, 2008.
7. Gofeld M: Anchoring of suboccipital lead: Case report and technical note. **Pain Pract** 4:307–309, 2004.
8. Haldeman S, Dagenais S: Cervicogenic headaches: A critical review. **Spine J** 1:31–46, 2001.
9. Hammer M, Doleys DM: Perineuromal stimulation in the treatment of occipital neuralgia: A case study. **Neuromodulation** 4:47–51, 2001.
10. Headache Classification Subcommittee of the International Headache Society: The International Classification of Headache Disorders: 2nd edition. **Cephalalgia** 24 [Suppl 1]:9–160, 2004.
11. Jasper J, Hayek SM: Implanted occipital nerve stimulators. **Pain Physician** 11:187–200, 2008.
12. Johnstone CS, Sundaraj R: Occipital nerve stimulation for the treatment of occipital neuralgia—Eight case studies. **Neuromodulation** 9:41–47, 2006.
13. Kapural L, Mekhail N, Hayek SM, Stanton-Hicks M, Malak O: Occipital nerve electrical stimulation via the midline approach and subcutaneous surgical leads for treatment of severe occipital neuralgia: A pilot study. **Anesth Analg** 101:171–174, 2005.
14. Kapural L, Stillman M, Kapural M, McIntyre P, Guirgius M, Mekhail N: Botulinum toxin occipital nerve block for the treatment of severe occipital neuralgia: A case series. **Pain Pract** 7:337–340, 2007.
15. Leone M, D'Amico D, Grazi L, Attanasio A, Bussone G: Cervicogenic headache: A critical review of the current diagnostic criteria. **Pain** 78:1–5, 1998.
16. Magis D, Allena M, Bolla M, De Pasqua V, Remacle JM, Schoenen J: Occipital nerve stimulation for drug-resistant chronic cluster headache: A prospective pilot study. **Lancet Neurol** 6:314–321, 2007.
17. Oh M, Ortega J, Bellotte J, Whiting D, Alo K: Peripheral nerve stimulation for the treatment of occipital neuralgia and transformed migraine using a C1–2–3 subcutaneous paddle style electrode: A technical report. **Neuromodulation** 7:103–112, 2004.
18. Picaza JA, Cannon BW, Hunter SE, Boyd AS, Guma J, Maurer D: Pain suppression by peripheral nerve stimulation. Part II. Observations with implanted devices. **Surg Neurol** 4:115–26, 1975.
19. Pöllmann W, Keidel M, Pfaffenrath V: Headache and the cervical spine: A critical review. **Cephalalgia** 17:801–816, 1997.
20. Slavin KV: Peripheral nerve stimulation for neuropathic pain. **Neurotherapeutics** 5:100–106, 2008.
21. Slavin KV, Colpan ME, Munawar N, Wess C, Nersesyan H: Trigeminal and occipital peripheral nerve stimulation for craniofacial pain: A single-institution experience and review of the literature. **Neurosurg Focus** 21(E6):1–5, 2006.
22. Slavin KV, Nersesyan H, Wess C: Peripheral neurostimulation for treatment of intractable occipital neuralgia. **Neurosurgery** 58:112–119, 2006.
23. Sjaastad O, Fredriksen TA, Pfaffenrath V: Cervicogenic headache: Diagnostic criteria. The Cervicogenic Headache International Study Group. **Headache** 38:442–445, 1998.
24. Sycha T, Kranz G, Auff E, Schnider P: Botulinum toxin in the treatment of rare head and neck pain syndromes: A systematic review of the literature. **J Neurol** 251 [Suppl 1]:19–30, 2004.
25. Trentman TL, Zimmerman RS: Occipital nerve stimulation: Technical and surgical aspects of implantation. **Headache** 48:319–27, 2008.
26. Waisbrod H, Panhans C, Hansen D, Gerbershagen HU: Direct nerve stimulation for painful peripheral neuropathies. **J Bone Joint Surg Br** 67(3):470–472, 1985.
27. Weiner RL, Reed KL: Peripheral neurostimulation for control of intractable occipital neuralgia. **Neuromodulation** 2:217–221, 1999.
28. Yannakakis GD: Occipital nerve block in intractable lateralized headaches: An effective treatment. **Headache** 39:386–387, 1999.