

Transcendent Leadership: Recent Advances in Pediatric Neurosurgery

Edward S. Ahn, M.D., and R. Michael Scott, M.D.

In this chapter, the authors review, in brief, what we think are the most substantial advances in the field of pediatric neurosurgery during the past decade. The decade has been marked by codification of the subspecialty of pediatric neurosurgery that is more rigorous and by notable advances in technology, in particular, the intraoperative magnetic resonance imaging (MRI) scan, refinements in neuroendoscopy, new operative instrumentation, and intraoperative imaging techniques. Collaborative studies on pediatric neurosurgical topics among institutions have flourished, and subspecialty education and certification have become a reality.

INTRAOPERATIVE MRI SCANNING

The intraoperative MRI scan has been an important development in the operative management of intracranial tumors, vascular malformations, and other lesions. In 1994, the open-configuration intraoperative MRI scanner was developed at the Brigham and Women's Hospital in Boston, Massachusetts.^{1,4} Its chief advantage over other forms of intraoperative image guidance seemed to be related to its capability of updating intraoperative imaging after changes in the position of anatomic structures after cerebrospinal fluid (CSF) egress and the delineation of extent of resection during tumor surgery. Imaging before extubation could demonstrate any postoperative hematomas or other potential surgical complications.

In 2005, the Children's Hospital in Boston installed and implemented the IMRIS ceiling-mounted 1.5-T MRI scanner for use in a dedicated magnetic resonance (MR) operating room, the first such facility in a pediatric hospital. As opposed to the fixed "double-doughnut" intraoperative MRI scanner developed at the Brigham and Women's Hospital, this scanner is a mobile unit that is moved away from the patient when not in use, permitting the use of standard operating instruments and microscope during surgery. The room itself is a standard large operating room (*Fig. 4.1A*), with the MRI scanner stored in a garage behind closed doors. In the middle of an operation, when a scan is deemed helpful, all ferromag-

netic equipment and instruments are counted and removed from the operative field, the patient, with head open, is wrapped in a sterile condom-like draping system, and the scanner is brought from its garage on overhead tracks to surround the craniotomy site (*Fig. 4.1, B and C*). This intraoperative MRI scanning concept seems to have significant clinical usefulness in pediatric neurosurgery. An important prognostic factor in many pediatric tumors is the extent of resection (ependymoma, medulloblastoma, astrocytoma, etc.), with the possibility of cure with or without adjuvant therapy significantly improved if total or nearly total resection can be performed. An intraoperative scan permits this confirmation while the patient is still under anesthesia. Further resection may then be performed, if necessary. An example of a standard case in which intraoperative imaging was useful in this respect is demonstrated in *Figure 4.2*. The accuracy of standard image guidance techniques during the operation has been considerably enhanced by the ability to perform registration scans after induction of anesthesia before craniotomy begins, with the patient in skeletal fixation and in the desired position for craniotomy. Moreover, the intraoperative MRI scan is proving to be a powerful clinical research tool.

This technology brings with it a significant cost in terms of installation, maintenance, and staffing. The system at the Children's Hospital in Boston was nearly seven million dollars in construction and equipment costs. In the operating room, by established protocol, there are three registered operating room nurses, and the MRI scan technician is either on site or on call at all times. Careful training in MRI scan safety and protocol for nurses and anesthesiologists is time consuming and costly. The length of each case is prolonged because of the demands of the intraoperative MRI scan protocol and the time taken for each intraoperative scan, which, at the time of preparation of this manuscript, was close to 45 minutes. Our anesthesia department will allow only one case per day to be operated on if intraoperative scans will be used. Perhaps the most important caveat of this new technology is that knowledge of the tumor's location and extent is no substitute for sound surgical judgment and good neuroanatomical knowledge. In addition, it is not always clear that the

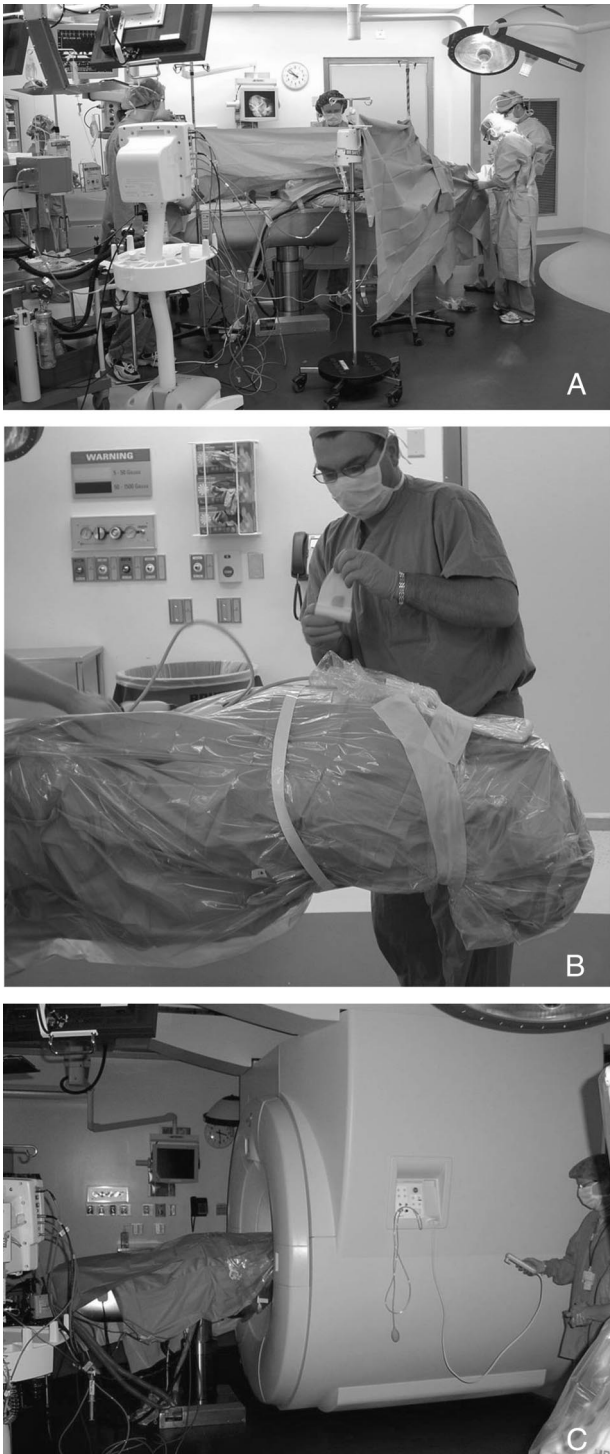

FIGURE 4.1. The intraoperative MRI scanner at the Children's Hospital in Boston is an IMRIS ceiling-mounted system. There is a dedicated operating room, which is a standard large operating room (A) with the MRI scanner stored in a garage behind closed doors. For imaging, the patient and the operating table are covered in sterile material (B) and the scanner slides from the garage along overhead tracks on the ceiling over the operating table (C).

MRI scan findings are closely correlated with the true extent of the pathological process. The surgical procedure itself will create artifact that, in a nonenhancing tumor that has a high signal on T2-weighted and fluid-attenuated inversion recovery MRI scans, may be mistaken for residual lesional tissue. We know that more technological advances, in particular, the development of a user-friendly system of intraoperative re-registration for frameless stereotactic image guidance, will make the intraoperative MRI scan an even more beneficial surgical adjunct.

NEUROENDOSCOPY

Neuroendoscopy has altered the standard neurosurgical treatment of obstructive hydrocephalus, and, during the past decade, third ventriculostomy using the endoscope has become one of the standard initial treatments of hydrocephalus because of aqueductal stenosis. Although aqueductal stenosis is frequently diagnosed on a congenital basis, and third ventriculostomy using the neuroendoscope has not been thought to be effective in very young children, the work of Warf,⁵ who used this technique in very young children with hydrocephalus of varying etiologies in Africa, has suggested that this technology may have wider application than what was initially thought. Its most common application in pediatric neurosurgery has been in the treatment of hydrocephalus caused by aqueductal stenosis or tumors in the pons or tectal region that cause obstruction at the cerebral aqueduct. During the past decade, the current standard of care for the treatment of hydrocephalus associated with pineal region tumors has been the neuroendoscopic treatment of hydrocephalus by third ventriculostomy, a technique that also allows sampling of CSF for cytology and markers, and in many cases, endoscopic biopsy of the tumor. The neuroendoscope has also changed our treatment of hydrocephalus associated with intraventricular cysts or septated ventricles, with the endoscope often able to treat by fenestration of an intraventricular cyst or by fenestrating multiple intraventricular cysts to permit the use of simple, single-catheter shunt systems. The endoscope is now used in many pediatric neurosurgical services to treat primary craniosynostosis, with early surgery with the endoscope used to perform simple suturectomy, and molding helmets used to continue the correction of cranial dysmorphism throughout the first year of life.

The use of the endoscope is not without its complications, and endoscopic procedures may cause intraventricular hemorrhage, or vascular and parenchymal injury, which may not be readily apparent at the time of the procedure. The fenestrations may close during many months after the procedure, leading to hydrocephalus recurrence. Neuroendoscopic procedures have a long and difficult learning curve, but there is no question that they have become a widely adopted advance in pediatric neurosurgical armamentarium during the past decade.

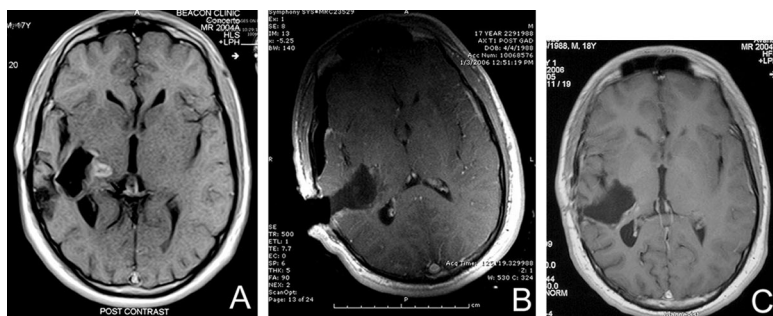


FIGURE 4.2. This series of MRI scans is from a 17-year-old boy with a multiply recurrent pilocytic astrocytoma. On his preoperative study (A), there is a recurrence deep in the previous surgical resection cavity demonstrated on axial T1-weighted postgadolinium images. He was brought to the operating room, where an intraoperative MRI scan taken before dural closure demonstrated complete resection of the tumor (B). This finding was confirmed 6 months later on a follow-up image (C).

INTRAOPERATIVE IMAGING AND INSTRUMENTATION

The past decade has also seen the increasing use of intraoperative ultrasound in the treatment of pediatric neurosurgical conditions. Intraoperative ultrasonography has been widely used across neurosurgical subspecialties because of its ability to localize lesions and to identify anatomical landmarks. In pediatric neurosurgical practice, ultrasound, in particular, facilitates the identification of vascular lesions, such as cavernous malformations and arteriovenous malformations, and can reliably localize deeper tumors and cysts. It can help to guide the surgeon in the placement of ventricular or cyst catheters. We have found that frequent use of this modality leads to more familiarity and increasing use of the technology.

Another major advance in technology has been the introduction of the yttrium-aluminum-garnet (YAG) laser, which has significantly improved the accuracy and safety of lesion resection and dissection. This tool has found multiple applications in the surgical treatment of pediatric neurosurgical disease. The dissecting tip and scalpel are ideal for releasing dural attachments in tethered cord surgery. The blunt tip will ablate tissue and is ideal for evaporation of fat in spinal lipomas or excision of deep tumor nodules where apertures of surgical approach are narrow. Use of the long fiber probe allows the surgeon to reach into areas where the ultrasonic aspirator or similar instruments may not fit. We have found this probe particularly useful to excise benign tumors in the brainstem or basal ganglia.

COLLABORATIVE PEDIATRIC NEUROSURGICAL PROJECTS

Some of the more significant advances in the practice of pediatric neurosurgery during the past decade have resulted from the collaboration between institutions on various projects. Because the neurosurgical diseases of the pediatric population only comprise a small subset within the entire field of neurosurgery, there is clear value in collaboration between institutions to understand these diseases, to evaluate the effectiveness of treatment, and, ultimately, to improve patient care. For example, the Endoscopic Shunt Insertion

Trial (ESIT) was a multicenter randomized trial that demonstrated that there was no reduction in shunt failure with endoscopic assisted insertion of ventricular catheters.² The Strata Valve Clinical Study was a prospective multicenter cohort trial of the Medtronic Strata adjustable shunt valve that involved investigators from 18 institutions, with the goal of evaluating the effectiveness of the Medtronic Strata adjustable shunt in treating hydrocephalus in children.³ The surgical management of “tethered cord syndrome” with the conus in normal position is currently being evaluated in a multi-institutional collaborative study. A pediatric neurosurgical “Listserve” has also been organized and is active on the Internet. By signing on to the service, a neurosurgeon can present a difficult or challenging case on the Internet and receive comments and advice from colleagues all over the world. This type of collaborative practice seems more readily applicable in pediatric neurosurgery because of the small size of pediatric neurosurgery and the familiarity of most practitioners in the subspecialty with one another.

SUBSPECIALTY EDUCATION AND CERTIFICATION

Among the various subspecialties in neurosurgery, pediatric neurosurgery seems to have made the most progress in standardization and regulation of fellowship training and certification. In reaction to the rejection by the American Board of Neurological Surgery (ABNS) and the Accreditation Council of Graduate Medical Education (ACGME) of standards for fellowship training in pediatric neurosurgery, the American Board of Pediatric Neurological Surgery (ABPNS) was formed in 1996. Candidates for this non-ACGME-approved board are required to be certified by the ABNS, to have completed an pediatric neurosurgical fellowship approved by the Accreditation Council of Pediatric Neurosurgical Fellowships (ACPNF), to submit an operative case log of 125 cases younger than age 12 years or 75% of all operative cases younger than age 21 years, to have satisfactory professional standing regarding licensure and hospital privileges, and to pass a written examination. The ABPNS prudently instituted a 10-year recertification cycle, which again requires the passage of a written exam, the submission

of adequate continuing medical education (CME) credits and pediatric operative case logs, and confirmation of adequate hospital credentials. At the time of preparation of this manuscript, three-fourths of the eligible diplomates had already completed the recertification process, and the ABPNS continues to gain new diplomates at the rate of 6 to 10 per year. From the standpoint of pediatric neurosurgery, the ready acceptance and flourishing of the ABPNS has been one of the sentinel events of the past decade.

CONCLUSION

Many of the recent advances in pediatric neurosurgery are also shared by other neurosurgical subspecialties. Although many newer technologies have impacted the entire field of neurosurgery, advances such as the intraoperative MRI scan, neuroendoscopy, and new intraoperative imaging and instrumentation seem to have particular applications in pediatric neurosurgical disorders. The small size of the pediatric neurosurgery community has facilitated cooperative studies and subspecialty consultation. Since the establishment of the ABPNS in 1996, there has been rapid acceptance of the

certification and recertification process, even by organized neurosurgery. It is hoped that the organization of pediatric neurosurgery into a defined subspecialty has set the groundwork for even further advances in surgical technology, education, and, ultimately, the care of children with neurosurgical disorders.

REFERENCES

1. Black PM, Moriarty T, Alexander E 3rd, Stieg P, Woodard EJ, Gleason PL, Martin CH, Kikinis R, Schwartz RB, Jolesz FA: Development and implementation of intraoperative magnetic resonance imaging and its neurosurgical applications. **Neurosurgery** 41(4):831–842, 1997.
2. Kestle JR, Drake JM, Cochrane DD, Milner R, Walker ML, Abbott R 3rd, Boop FA: Endoscopic Shunt Insertion Trial participants. Lack of benefit of endoscopic ventriculoperitoneal shunt insertion: A multicenter randomized trial. **J Neurosurg** 98(2):284–290, 2003.
3. Kestle JR, Walker ML, Strata Investigators: A multicenter prospective cohort study of the Strata valve for the management of hydrocephalus in pediatric patients. **J Neurosurg** 102(2 Suppl):141–145, 2005.
4. Mittal S, Black PM: Intraoperative magnetic resonance imaging in neurosurgery: The Brigham concept. **Acta Neurochir Suppl** 98:77–86, 2006.
5. Warf BC: Hydrocephalus in Uganda: The predominance of infectious origin and primary management with endoscopic third ventriculostomy. **J Neurosurg** 102 (1 Suppl):1–15, 2005.