

# Malignant Brain Tumors: Two Steps Forward

*Stéphanie Puget, M.D. and James T. Rutka, M.D, Ph.D*

There have been many recent advances in our knowledge of the molecular biology of human malignant brain tumors. However, these have not been translated for the most part into a demonstrable improvement in the prognosis of patients harboring such tumors. That being said, tangible benefits have accrued in the past few years to adult patients with glioblastoma multiforme (GBM), and to children with medulloblastoma, because of developments in new technologies that have elucidated the molecular underpinnings that characterize these two malignant brain tumors. Today, it is clear that scientific advancements will not be born in a vacuum. Rather, we need to develop networks of neurosurgeons, scientists, and biostatisticians to bring clarity to the enormous amount of data that are accumulating in various gene repositories from microarray experimentation. Working together, such networks will catalyze our abilities to stratify patients according to molecular markers and to provide optimum therapy to extend their survival and improve their quality of life. In this review, we focus our attention on the recent advances in the molecular biology of human gliomas and medulloblastomas—the two most common malignant brain tumors in adults and children.

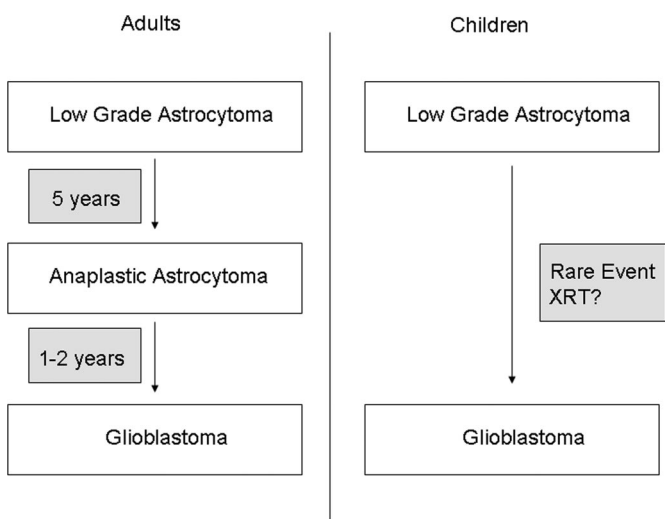
## PROGRESSION IN GLIOMAS

Low-grade gliomas (LGGs) belong to a heterogeneous group of tumors, with more than 10 subgroups described in the World Health Organization (WHO) classification. Their management is controversial with regard to surgical resection, the use and the optimal timing of radiation therapy, and the effectiveness of chemotherapy. Despite their nonmalignant histological features, LGGs can transform to a higher-grade malignancies in adults.<sup>18</sup> With rare exceptions, the anaplastic transformation of a LGG in an adult will take place within 5 to 7 years after initial diagnosis. Interestingly, the transformation of a LGG to a higher-grade malignancy in a child is a rare event and is often associated with previous administration of radiation therapy<sup>7</sup> (*Fig. 2.1*). This difference between pediatric and adult gliomas is remarkable, and is also reflected in their location. Gliomas in the pediatric population have a tendency to occur in the optic pathways

and cerebellum. Moreover, the classic histology encountered in adult LGGs consists of fibrillary astrocytoma, whereas, in children, it is a pilocytic astrocytoma. Taken together, these data support the notion that the pathogenesis of pediatric and adult gliomas is distinct. This is in keeping with the data from array-based comparative genomic hybridization (CGH) and gene profiling expression studies, which show that there are less distinct genomic alterations in gliomas in children.<sup>4,36</sup>

Despite several studies, the role of the extent of surgical resection in adult patients with LGGs is still controversial. This is in no small part because of the heterogeneity of patients studied in published series, and in the differences in methodologies used to measure extent of resection. There have been no prospective randomized trials performed to answer the question regarding the role of surgery for LGGs. In 2005, Claus et al. reported on 156 patients with LGGs who underwent surgery using intraoperative magnetic resonance imaging (MRI) scans to achieve as great a resection as possible. They reported an association between surgical resection and overall patient survival. Patients who underwent subtotal resection were at 1.4 times the risk of disease recurrence (95% confidence interval [CI], 0.7–3.1) and at 4.9 times the risk of death (95% CI, 0.61–40.0) compared with patients who underwent gross total resection.<sup>5</sup>

Data from recent randomized trials have helped to guide clinical decision making in treating patients with LGGs with radiation therapy. The European Organization of Research and Treatment of Cancer (EORTC) Radiotherapy and Brain Tumor Groups initiated a prospective trial in 1986, to compare early radiation therapy with delayed radiation therapy at the time of tumor progression. One hundred fifty-seven patients were assigned to each group. They found that early radiation therapy lengthens the time to progression, but does not influence overall patient survival.<sup>33</sup> Accordingly, at this time, there is no consensus regarding the optimal timing for radiation therapy for all patients with LGGs. However, in some cases, especially in those patients with poor prognostic factors, such as age older than 40 years, Karnofsky Performance Scale less than 70, a high MIB-1 index, the presence of a neurological deficit, and tumor contrast enhancement on imaging studies, early radiation therapy is generally recommended. The role of chemotherapy in LGGs in adults remains to be determined. However, LGGs in children are frequently



**FIGURE 2.1.** The typical evolution of an LGG in adults to a GBM passes through an anaplastic astrocytoma phase. Typically, patients will progress from low-grade to high-grade neoplasms in the time frame of 5 to 7 years after the diagnosis of LGG. By way of contrast, the progression of an LGG in a child to a higher-grade malignancy is a rare event, and is usually associated with other factors, such as previously administered radiation therapy, or an underlying familial cancer syndrome.

being treated with chemotherapy with good outcomes for disease stabilization and regression over time.<sup>9,21,27,34</sup>

**THE PATHWAYS TO GLIOMA PROGRESSION**

The known tendency of adult LGGs to progress to a higher-grade lesion has led to studies regarding the molecular pathways that are dysregulated at each step along the way. Several studies have shown that the progression of LGGs is the direct result of an accumulation of genetic abnormalities that occur stepwise in a process that is reminiscent of the changes that take place in colonic cancer.<sup>15,26</sup>

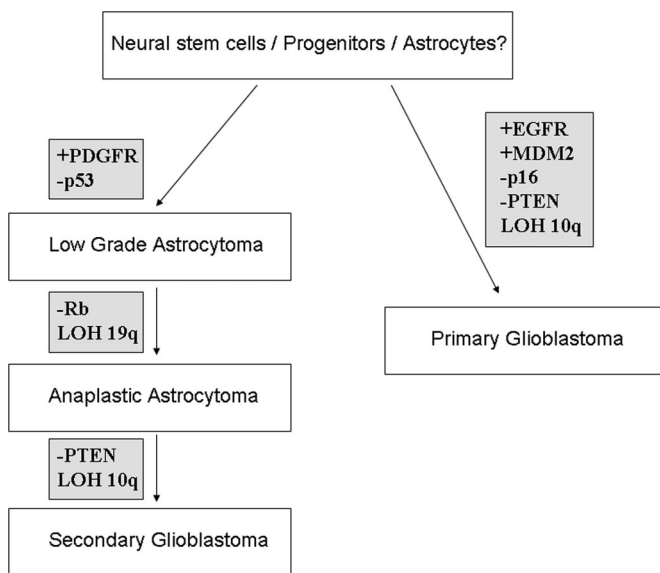
For gliomas, there are two main early alterations that are both mutually exclusive: the first is the mutation of *p53* on chromosome 17p, which is found in more than 50% of patients with LGGs; and the second is the deletion of 1p/19q, which is fairly specific for oligodendrogliomas. The overexpression of platelet-derived growth factor (PDGF) and its receptor is also observed in the early stage of glioma progression. Anaplastic astrocytomas often have deletion of p16/CDKN2A (chromosome 9p21), inactivation of *RB1* (chromosome 13q), amplification of *CDK4*, and loss of 19q. Subsequent progression to GBM typically involves loss of chromosome 10q. Here, the gene deletion of prime interest is the tumor suppressor gene, *PTEN*, which is lost or mutated in the majority of patients. A GBM that arises from a LGG as a result of several acquired genetic hits is called a “secondary GBM.” We also know now that GBM may arise de novo

without going through a LGG phase. These GBMs are called “primary GBMs” and typically arise from loss of *PTEN* and amplification of the epidermal growth factor receptor (EGFR) (Fig. 2.2).

In general, the molecular genetic abnormalities that comprise malignant gliomas belong to three main pathways involved in glioma oncogenesis: 1) the p53 pathway (by inactivation of *p53* or *p14/ARF* or the amplification of *MDM2*); 2) the *RB1* pathway (by its inactivation, the amplification of *CDK4* or the inactivation of *p16/CDKN2A*); and 3) the tyrosine kinase receptor signaling pathway (amplification of *EGFR* or *PDGF* receptor, or the inactivation of *PTEN*). Interestingly, these genetic alterations that characterize adult gliomas, especially the amplification of *EGFR*, are rarely encountered in pediatric gliomas.<sup>32,36</sup>

**MALIGNANT GLIOMAS: A STANDARD OF CARE?**

Surgery and radiation therapy have been the cornerstones of malignant glioma therapy, and have limited success in terms of long-term survival. Is there a role for aggressive surgical resection in prolonging survival of patients with GBM? Several studies have been performed to try to answer



**FIGURE 2.2.** Molecular genetics of adult astrocytomas. GBMs may arise in at least two different ways. One is the “secondary glioblastoma,” so called because it arises secondary to a number of well-defined genetic hits, as listed. The other is the “primary glioblastoma,” because it arises without passing through a well-defined time period, and is the result of numerous genetic lesions appearing simultaneously in the tumor. Interestingly, the genetic hits for primary and secondary glioblastoma are somewhat different. In addition, most of the identified genetic lesions affect genes that control cell cycle or growth factor activation pathways.

this question. The 2-year survival in these series is still less than 30%. Perhaps the best series that examined the role of surgery for GBM was performed by Lacroix et al., in which these authors studied 416 patients who underwent surgery for GBM. They concluded that at least 98% of the tumor has to be resected to show a significant survival advantage compared with a worse survival with a less radical resection (median survival, 13 versus 8.8 mo).<sup>17</sup>

What about the role of chemotherapy for adult GBM? In the past, several trials with different chemotherapy agents have shown a negligible benefit.<sup>1,25</sup> However, a recent Phase III trial has been conducted comparing radiation therapy alone with radiation therapy and concurrent adjuvant temozolomide (TMZ) in patients with newly diagnosed GBM.<sup>31</sup> In this trial, TMZ improved the outcome of patients with GBM to 27% at 24 months versus 10% at 24 months for the radiation therapy-alone group. This regimen should be considered as the new “standard of care” in the treatment of patients with malignant gliomas. As emphasized by DeAngelis,<sup>6</sup> the concurrent administration of TMZ chemotherapy with radiation therapy has played an important role in enhancing the overall outcome of patients with GBM and suggests that chemotherapy is offering these patients a “new beginning.”

It is now clear that the methylation status of the methyl guanine methyl transferase (*MGMT*) promoter seems to predict the response to treatment by TMZ in GBM.<sup>10</sup> The *MGMT* gene is involved in the repair of deoxyribonucleic acid (DNA) damage caused by alkylating or methylating chemotherapeutic agents and its action is silenced by DNA methylation. In a follow-up study, Hegi et al.<sup>10</sup> showed that the prognosis was better for patients with GBM whose tumors showed *MGMT* promoter methylation than for those patients whose tumors did not. *MGMT* promoter methylation studies can now be performed on GBM specimens using either immunohistochemistry or a methylation-specific polymerase chain reaction (PCR) assay.

Accordingly, we are entering an era in which chemotherapy has shown some promise in the treatment of adult patients with GBM. These advances have been realized on the basis of prospective randomized trials with a collaboration of many clinical centers. Continuing these efforts will allow further biological factors to be identified that may help subsets of patients with GBM.

### OLIGODENDROGLIOMAS: THE 1P/19Q PARADIGM

Patients with oligodendroglioma have perhaps benefited the most from advances in the molecular genetics of brain tumors. The deletion of 1p and 19q occurs early in tumorigenesis and has been described in 50 to 70% of patients with low-grade oligodendrogliomas. The relevance of this genetic signature is that it is predictive of the tumor's

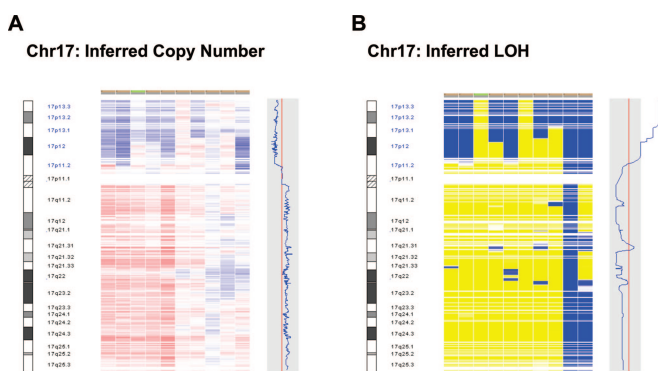
chemosensitivity to agents such as procarbazine, carmustine, and vincristine (PCV) or TMZ. Longer survival times have accrued to patients with anaplastic oligodendroglioma bearing 1p/19q deletions.<sup>12,14</sup> Interestingly, a large-scale genomic analysis by array-CGH on 108 patients distinguished two different patterns of 1p deletion in terms of prognostic factors. The first involves a deletion of the whole of 1p (associated with the deletion of the whole 19q) and is related to a good prognosis in oligodendrogliomas; whereas the second is a partial 1p deletion (not associated with 19q loss), which has a negative prognostic value and is mostly associated with astrocytomas.<sup>11</sup> Recently, the results of a large study on more than 100 oligodendrogliomas using fluorescein in situ hybridization (FISH) strongly suggested that a translocation t(1;19)(q10;p10) mediates the combined 1p/19q deletion. Moreover, this translocation was also associated with superior overall survival and progression-free survival.<sup>13</sup> Finally, these chromosomal alterations have also been associated with radiological features, in that 1p/19q deletions are most frequently found in oligodendrogliomas in a frontal location. In addition, a retrospective MRI scan study of 40 cases found an indistinct border on T1-weighted MRI scans and mixed signal intensity on T1- and T2-weighted MRI scans with the 1p/19q deletion.<sup>19</sup> These data need to be confirmed in larger prospective studies, but represent an exciting example of the association between genotype and phenotype.

Even if the genes involved in the pathogenesis of oligodendroglioma on chromosomes 1p and 19q are not yet known, the results of molecular analyses of these tumors will influence their management. One of the candidate genes that has been proposed is the tumor suppressor gene, *P190RhoGAP*, localized on 19q13.3.<sup>35</sup> Undoubtedly, we will learn more of this candidate gene, and others, in the near future.

### MEDULLOBLASTOMA

Medulloblastoma is a heterogeneous malignant tumor occurring primarily in childhood. Just as with malignant gliomas, it is now common clinical practice to try to stratify patients according to various clinical, pathological, and molecular genetic information. For some time now, patients with medulloblastoma have been segregated according to identified risk factors. These include a low-risk group for age older than 3 years, less than 1.5 cm<sup>2</sup> of residual tumor, and no demonstrable metastases; and a high-risk group for age younger than 3 years, the presence of residual tumor measuring more than 1.5 cm<sup>2</sup>, and the presence of metastases.

The role of surgery has been assessed in the Children's Cancer Group (CCG) study 921,<sup>3</sup> which confirmed that the extent of resection correlated with better survival in the nonmetastatic group. As such, gross total resection remains a major goal in the therapeutic management of patients with medulloblastoma, and is reflected in the success that has been



**FIGURE 2.3.** Detection of allelic imbalance in brain tumours using high-density SNP arrays. Modern SNP array platforms provide both DNA copy number and SNP genotype data at an average resolution of less than 10 kilobases. SNP genotypes can be used to identify genomic regions which have undergone loss of heterozygosity (LOH) in tumours. [A], Inferred copy number view of chromosome 17 for 10 MB cell lines analyzed by SNP array. Copy number for each sample is shown in the middle panel, with losses depicted in blue and gains in red. The panel on the right displays the copy number profile for one MB cell line with loss of 17p and gain of 17q (isochromosome 17q). [B], Inferred LOH view of the same MB cell lines shown in [A]. The middle panel depicts retention of heterozygosity in yellow and predicted LOH in blue. The prevalence of LOH on 17p in these samples is demonstrated by the significance curve (blue line) on the right. Figure courtesy of Paul Northcott; University of Toronto, Toronto, Canada.

established in the treatment of this disease. Furthermore, it has been shown that the chances of achieving a gross total resection, and, as a result, a better long-term survival, may be better in neurosurgical units dedicated to the care of the child with neurosurgical disease.<sup>2,30</sup>

In the past two decades, efforts have been made to improve the outcome of high-risk patients and to reduce the secondary effects of radiation therapy on cognitive function. In 1994, Packer et al.<sup>22</sup> showed that chemotherapy has a definite role to play in the management of medulloblastoma. His results showed progression-free survivals at 5 years of 85% for the entire group, 67% for the metastatic group, and 90% for the local disease group. Obviously, these results take us a quantum leap forward in survival since the days of Cushing when virtually all patients died within 1 to 2 years of diagnosis. To delay or obviate the need for radiation therapy, especially in children younger than age 3 years, several postoperative intensive chemotherapy trials have been undertaken. In a recent study by Rutkowski et al.,<sup>24</sup> lengthy remissions after chemotherapy alone were achieved with overall survival and progression-free survival comparable with studies in which radiation therapy and chemotherapy were used together. The results from the cognitive tests in this study showed that intelligence quotient (IQ) score tests were higher when patients were treated with chemotherapy alone,

and when radiation therapy was not used. Although it would be a desirable goal to avoid the injurious effects of radiation therapy in all patients with medulloblastoma, at present this is not possible. Craniospinal irradiation will remain an important adjunct treatment for the child with medulloblastoma until many more studies with chemotherapy alone are completed.

The current best treatment for medulloblastoma consists of a maximum safe neurosurgical resection followed by a reduced dose of craniospinal irradiation, except in the child younger than age 3 years in whom radiation therapy should be avoided. Autologous stem cell transplant has become widely used to limit the adverse effects of chemotherapy, and to maximize the dose of chemotherapeutic agents that can be used. With such multimodal treatment, the 5-year survival for patients with medulloblastoma is currently estimated at 70 to 80% for the average-risk group, and 50% for the high-risk group.

The application of tissue microarray technology to medulloblastoma has uncovered several biological markers that can predict for disease outcome.<sup>23</sup> Some of these include Trk C, p53, c-myc, and ErbB2. No doubt, in the future, as these targets become increasingly recognized and verified, we will have new targeted therapies for medulloblastoma with anticipated better outcomes.

## MALIGNANT BRAIN TUMORS—THE CANCER STEM CELL PARADIGM

In recent years, it is becoming clear that many cancers may be derived from primitive precursors, or “stem cells.” This is also the case for human malignant brain tumors.<sup>28,29</sup> One of the current challenges in all cancer types is the targeting of “cancer stem cells” (CSC), which are comprised of a very limited population of cells within the tumor bulk.<sup>29</sup> CSCs have indefinite potential for self-renewal, thus, driving tumorigenesis, and they are resistant to traditional therapies that are typically aimed at the more differentiated tumor cells. At the present time, there are no fully reliable and specific surface markers for CSCs within solid tumors, and, hence, no specific treatment modalities can be used against them. The current challenge is to purify the subpopulation of CSCs, characterize them fully from both a molecular genetic and phenotypic standpoint, and then to elucidate the molecular pathways that underlie their self-renewal and differentiation properties. This will likely be feasible using some of the newer technologies that are described in the next two sections.

## THE PROMISE OF ONCOGENOMICS

The field of oncogenomics has progressed rapidly with the development of new methods to assess genetic alterations that occur across the entire genome in a single experiment (Fig. 3.3). Some of these techniques include spectral karyo-

typing (SKY), which identifies structural aberrations on metaphase chromosomes from cultured cells using fluorescence microscopy; CGH, which can map regions of gains or losses of genetic material across all chromosomes; array-CGH, which is a technique that requires a microarray platform using bacterial artificial chromosomes (BACs) or oligonucleotides, thus, providing better resolution than CGH by itself; and the single nucleotide polymorphism (SNP) array, which is a technique based on the most commonly occurring variations in DNA in the human genome. The SNP chip can now provide a 2000-bp resolution when the 500,000 SNP-chip array is used. This particular technique now enables a scientist to identify a gene that may be deleted or amplified in the cancer genome without needing to resort to a large amount of DNA sequencing (*Fig. 2.3*).

These techniques have clearly impacted our abilities to classify malignant brain tumors, and have been linked in several studies to better correlations with patient outcome than could be accomplished using standard histological classification systems alone.<sup>20</sup> Recently, Kotliarov et al.<sup>16</sup> performed SNP-array study on a large series of 178 GBMs. These authors were able to confirm genetic alterations previously reported for GBM, and refine the locations of many suspected new genetic lesions in these tumors.

### THE MINIATURIZATION OF SCIENCE

One of the promising advances in the “chip-based” technology described above is the miniaturization of science, which refers to the performance of chemical and biological research using the “lab on a chip” approach (*Fig. 2.4*). All of

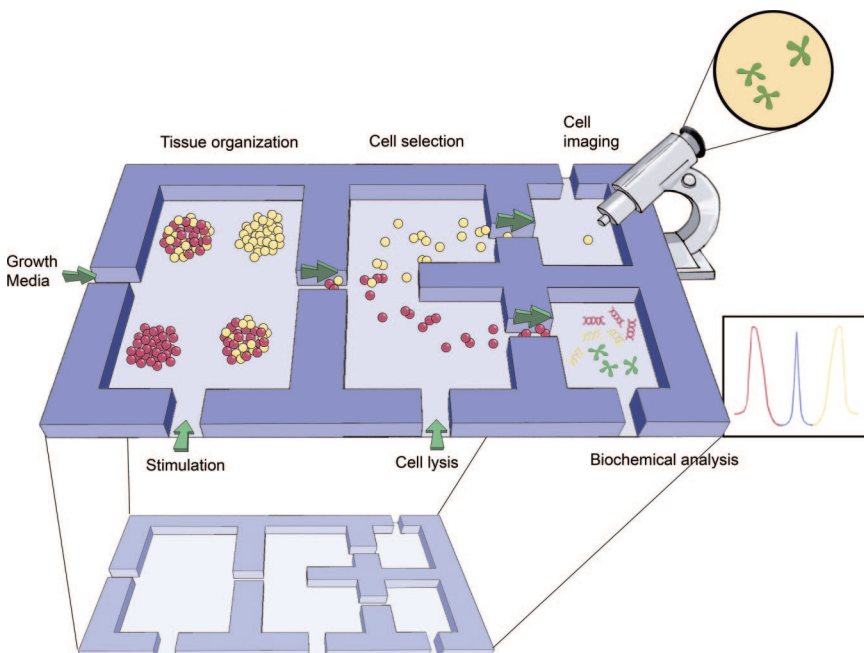
the new tools currently at our disposal to study the genetics of human malignant brain tumors can be brought together on a micrometer scale. Microtechnologies and nanotechnologies enable us to perform experiments studying the genetic composition of a given cell population and its cell growth capabilities and responses to treatment, all within the confines of a small glass slide. No longer is a large laboratory space required to perform these experiments. It is possible now to use microsystems to perform cell-based assays, cell culture, cell sorting, sophisticated cell imaging, and subcellular protein and genetic analyses in an automated format.<sup>8</sup> The days when large labs were required to investigate the genetic underpinnings of human brain tumors will soon be over!

### TWO STEPS FORWARD

We have reviewed some of the data that have provided optimism for the treatment of the patient with GBM or medulloblastoma. Although we may have taken two steps forward in our treatment of these tumors, we must now take one step back. Why? First, too many patients with GBM continue to relapse and progress with their disease. Second, we still rely too heavily on toxic therapies, such as aggressive chemotherapy or radiation therapy. The challenge for the future will be to transfer our knowledge from the world of basic science into effective therapeutic approaches for patients with malignant brain tumors.

### Acknowledgment

This work was supported through funds from the Canadian Institutes of Health Research.



**FIGURE 2.4.** Schematic representation of a microsystem integrating cell culture and microimaging techniques to perform biochemical, gene profiling, and response to therapy analyses. This is a “lab on a chip” approach to science, and is part of the miniaturization of large scale lab efforts (adapted from El Ali J, Sorger PK, Jensen KF: Cells on chips. *Nature* 442:403–411, 2006<sup>8</sup>).

## REFERENCES

1. Randomized trial of procarbazine, lomustine, and vincristine in the adjuvant treatment of high-grade astrocytoma: a Medical Research Council trial. *J Clin Oncol* 19:509–518, 2001.
2. Albright AL, Sposto R, Holmes E, Zeltzer PM, Finlay JL, Wisoff JH, Berger MS, Packer RJ, Pollack IF: Correlation of neurosurgical subspecialization with outcomes in children with malignant brain tumors. *Neurosurgery* 47:879–885, 2000.
3. Albright AL, Wisoff JH, Zeltzer PM, Boyett JM, Rorke LB, Stanley P: Effects of medulloblastoma resections on outcome in children: A report from the Children's Cancer Group. *Neurosurgery* 38:265–271, 1996.
4. Cheng Y, Ng HK, Zhang SF, Ding M, Pang JC, Zheng J, Poon WS: Genetic alterations in pediatric high-grade astrocytomas. *Hum Pathol* 30:1284–1290, 1999.
5. Claus EB, Horlacher A, Hsu L, Schwartz RB, Dello-Iacono D, Talos F, Jolesz FA, Black PM: Survival rates in patients with low-grade glioma after intraoperative magnetic resonance image guidance. *Cancer* 103:1227–1233, 2005.
6. DeAngelis LM: Chemotherapy for brain tumors—A new beginning. *N Engl J Med* 352:1036–1038, 2005.
7. Dirks PB, Jay V, Becker LE, Drake JM, Humphreys RP, Hoffman HJ, Rutka JT: Development of anaplastic changes in low-grade astrocytomas of childhood. *Neurosurgery* 34:68–78, 1994.
8. El Ali J, Sorger PK, Jensen KF: Cells on chips. *Nature* 442:403–411, 2006.
9. Gururangan S, Cavazos CM, Ashley D, Herndon JE, Bruggers CS, Moghrabi A, Scarcella DL, Watral M, Tourt-Uhlig S, Reardon D, Friedman HS: Phase II study of carboplatin in children with progressive low-grade gliomas. *J Clin Oncol* 20:2951–2958, 2002.
10. Hegi ME, Diserens AC, Gorlia T, Hamou MF, de Tribolet N, Weller M, Kros JM, Hainfellner JA, Mason W, Mariani L, Bromberg JE, Hau P, Mirimanoff RO, Cairncross JG, Janzer RC, Stupp R: MGMT gene silencing and benefit from temozolomide in glioblastoma. *N Engl J Med* 352:997–1003, 2005.
11. Idbaih A, Marie Y, Pierron G, Brennetot C, Hoang-Xuan K, Kujas M, Mokhtari K, Sanson M, Lejeune J, Aurias A, Delattre O, Delattre JY: Two types of chromosome 1p losses with opposite significance in gliomas. *Ann Neurol* 58:483–487, 2005.
12. Ino Y, Betensky RA, Zlatescu MC, Sasaki H, Macdonald DR, Stemmer-Rachamimov AO, Ramsay DA, Cairncross JG, Louis DN: Molecular subtypes of anaplastic oligodendroglioma: Implications for patient management at diagnosis. *Clin Cancer Res* 7:839–845, 2001.
13. Jenkins RB, Blair H, Ballman KV, Giannini C, Arusell RM, Law M, Flynn H, Passe S, Felten S, Brown PD, Shaw EG, Buckner JC: A t(1;19)(q10;p10) mediates the combined deletions of 1p and 19q and predicts a better prognosis of patients with oligodendroglioma. *Cancer Res* 66:9852–9861, 2006.
14. Jeuken JW, von Deimling A, Wesseling P: Molecular pathogenesis of oligodendroglial tumors. *J Neurooncol* 70:161–181, 2004.
15. Kinzler KW, Vogelstein B: Cancer-susceptibility genes. Gatekeepers and caretakers. *Nature* 386:761, 763, 1997.
16. Kotliarov Y, Steed ME, Christopher N, Walling J, Su Q, Center A, Heiss J, Rosenblum M, Mikkelsen T, Zenklusen JC, Fine HA: High-resolution global genomic survey of 178 gliomas reveals novel regions of copy number alteration and allelic imbalances. *Cancer Res* 66:9428–9436, 2006.
17. Lacroix M, Abi-Said D, Fournier DR, Gokaslan ZL, Shi W, DeMonte F, Lang FF, McCutcheon IE, Hassenbusch SJ, Holland E, Hess K, Michael C, Miller D, Sawaya R: A multivariate analysis of 416 patients with glioblastoma multiforme: Prognosis, extent of resection, and survival. *J Neurosurg* 95:190–198, 2001.
18. Mandonnet E, Delattre JY, Tanguy ML, Swanson KR, Carpentier AF, Duffau H, Cornu P, Van Effenterre R, Alvard EC Jr, Capelle L: Continuous growth of mean tumor diameter in a subset of grade II gliomas. *Ann Neurol* 53:524–528, 2003.
19. Megyesi JF, Kachur E, Lee DH, Zlatescu MC, Betensky RA, Forsyth PA, Okada Y, Sasaki H, Mizoguchi M, Louis DN, Cairncross JG: Imaging correlates of molecular signatures in oligodendrogliomas. *Clin Cancer Res* 10:4303–4306, 2004.
20. Nutt CL, Mani DR, Betensky RA, Tamayo P, Cairncross JG, Ladd C, Pohl U, Hartmann C, McLaughlin ME, Batchelor TT, Black PM, von Deimling A, Pomeroy SL, Golub TR, Louis DN: Gene expression-based classification of malignant gliomas correlates better with survival than histological classification. *Cancer Res* 63:1602–1607, 2003.
21. Packer RJ: Chemotherapy: Low-grade gliomas of the hypothalamus and thalamus. *Pediatr Neurosurg* 32:259–263, 2000.
22. Packer RJ, Sutton LN, Elterman R, Lange B, Goldwein J, Nicholson HS, Mulne L, Boyett J, D'Angio G, Wechsler-Jentsch K, et al.: Outcome for children with medulloblastoma treated with radiation and cisplatin, CCNU, and vincristine chemotherapy. *J Neurosurg* 81:690–698, 1994.
23. Ray A, Ho M, Ma J, Parkes RK, Mainprize TG, Ueda S, McLaughlin J, Bouffet E, Rutka JT, Hawkins CE: A clinicobiological model predicting survival in medulloblastoma. *Clin Cancer Res* 10:7613–7620, 2004.
24. Rutkowski S, Bode U, Deinlein F, Ottensmeier H, Warmuth-Metz M, Soerensen N, Graf N, Emser A, Pietsch T, Wolff JE, Kortmann RD, Kuehl J: Treatment of early childhood medulloblastoma by postoperative chemotherapy alone. *N Engl J Med* 352:978–986, 2005.
25. Shapiro WR, Green SB, Burger PC, Mahaley MS Jr, Selker RG, VanGilder JC, Robertson JT, Ransohoff J, Mealey J Jr, Strike TA, et al.: Randomized trial of three chemotherapy regimens and two radiotherapy regimens and two radiotherapy regimens in postoperative treatment of malignant glioma. Brain Tumor Cooperative Group Trial 8001. *J Neurosurg* 71:1–9, 1989.
26. Sidransky D, Mikkelsen T, Schwegheimer K, Rosenblum ML, Cavance W, Vogelstein B: Clonal expansion of p53 mutant cells is associated with brain tumour progression. *Nature* 355:846–847, 1992.
27. Silva MM, Goldman S, Keating G, Marymont MA, Kalapurakal J, Tomita T: Optic pathway hypothalamic gliomas in children under three years of age: The role of chemotherapy. *Pediatr Neurosurg* 33:151–158, 2000.
28. Singh SK, Clarke ID, Terasaki M, Bonn VE, Hawkins C, Squire J, Dirks PB: Identification of a cancer stem cell in human brain tumors. *Cancer Res* 63:5821–5828, 2003.
29. Singh SK, Hawkins C, Clarke ID, Squire JA, Bayani J, Hide T, Henkelman RM, Cusimano MD, Dirks PB: Identification of human brain tumour initiating cells. *Nature* 432:396–401, 2004.
30. Smith ER, Butler WE, Barker FG: Craniotomy for resection of pediatric brain tumors in the United States, 1988 to 2000: Effects of provider caseloads and progressive centralization and specialization of care. *Neurosurgery* 54:553–563, 2004.
31. Stupp R, Mason WP, Van den Bent MJ, Weller M, Fisher B, Taphoorn MJ, Belanger K, Brandes AA, Marosi C, Bogdahn U, Curschmann J, Janzer RC, Ludwin SK, Gorlia T, Allgeier A, Lacombe D, Cairncross JG, Eisenhauer E, Mirimanoff RO: Radiotherapy plus concomitant and adjuvant temozolomide for glioblastoma. *N Engl J Med* 352:987–996, 2005.
32. Sung T, Miller DC, Hayes RL, Alonso M, Yee H, Newcomb EW: Preferential inactivation of the p53 tumor suppressor pathway and lack of EGFR amplification distinguish de novo high grade pediatric astrocytomas from de novo adult astrocytomas. *Brain Pathol* 10:249–259, 2000.
33. Van den Bent MJ, Afra D, de Witte O, Ben Hassel M, Schraub S, Hoang-Xuan K, Malmstrom PO, Collette L, Pierart M, Mirimanoff R, Karim AB: Long-term efficacy of early versus delayed radiotherapy for low-grade astrocytoma and oligodendroglioma in adults: The EORTC 22845 randomised trial. *Lancet* 366:985–990, 2005.
34. Walter AW, Gajjar A, Reardon DA, Thompson SJ, Langston JW, Jones-Wallace D, Kun LE, Heideman RL: Tamoxifen and carboplatin for children with low-grade gliomas: A pilot study at St. Jude Children's Research Hospital. *J Pediatr Hematol Oncol* 22:247–251, 2000.
35. Wolf RM, Draghi N, Liang X, Dai C, Uhrbom L, Eklof C, Westermark B, Holland EC, Resh MD: p190RhoGAP can act to inhibit PDGF-induced gliomas in mice: A putative tumor suppressor encoded on human chromosome 19q13.3. *Genes Dev* 17:476–487, 2003.
36. Wong KK, Tsang YT, Chang YM, Su J, Di Francesco AM, Meco D, Riccardi R, Perlaky L, Dauser RC, Adesina A, Bhattacharjee M, Chintagumpala M, Lau CC: Genome-wide allelic imbalance analysis of pediatric gliomas by single nucleotide polymorphic allele array. *Cancer Res* 66:11172–11178, 2006.