

Introduction

Warfarin-associated intracerebral hemorrhage (ICH) is often results in poor prognosis due to hematoma expansion under uncorrected coagulopathy. Recently, rapid reversal of vitamin K antagonist by four-factor prothrombin complex concentrates (4F-PCC) was shown to be superior to fresh frozen plasma (FFP), in terms of rapid prothrombin time-internal normalized ratio (PT-INR) reversal and effective hemostasis for urgent surgical or invasive procedures, but PCC has still not been approved by Ministry of Health, Labor and Welfare in Japan. The aim of this study was to elucidate the effect of 4F-PCC in comparison with FFP for hematoma expansion and clinical outcome after warfarin-associated ICH.

protocol of PCC administration

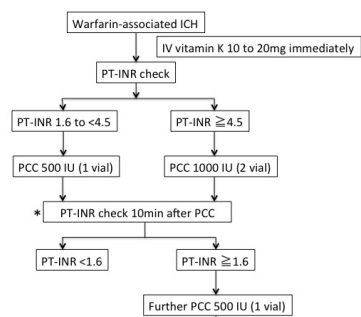


Fig1.

Demographics and baseline characteristics

	PCC group (n=24)	FFP group (n=33)	p value
age	72.2 ± 11.6	72.0 ± 10.3	0.94
female sex	5	12	0.25
reason for warfarin			
atrial fibrillation	16	21	
artificial heart valve	6	9	
thromboembolic event	1	1	
heart failure	1	2	
baseline PT-INR	2.65 ± 0.72	2.40 ± 0.80	0.23
baseline platelet count	17.7 ± 8.0	17.2 ± 6.4	0.97
hematoma volume	18.0 ± 25.0	18.4 ± 25.8	0.95
hypertension %(n)	79% (19)	89% (23)	0.54
antiplatelet %(n)	50% (12)	45% (15)	0.79
NIHSS on admission	11.1 ± 10.5	10.2 ± 10.3	0.73

Methods

We retrospectively reviewed 40 patients with ICH who was taking warfarin at the initial diagnosis of it and treated with 4F-PCC from January 2010 to August 2014. In these cases, we excluded 1 case whose PT-INR was less than 1.6, 1 case whose etiology of ICH was arteriovenous malformation, 6 cases who were not treated intensively because of irreversible brain damage on CT, and 8 cases who underwent urgent hematoma removal. As control group, we examined 33 warfarin associated ICH cases treated with FFP. Baseline characteristics such as age, gender, location of hematoma, hematoma volume, and various hematological factors such as platelet count was collected from the medical records. The extent of hematoma expansion calculated through serial head CT scans, modified Rankin scale (mRS) at discharge, and adverse events attributable to 4F-PCC or FFP were compared between those treated with 4F-PCC (4F-PCC group) and fresh frozen plasma (FFP group).

PT-INR values before(Pre), after(Post) and 6-20h after administration of PCC

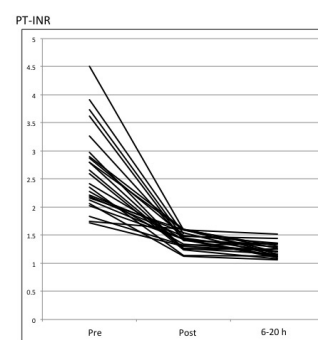


Fig2.

Results

In the 4F-PCC group, PT-INR was corrected from 2.65±0.72 to 1.41±0.14 (p<0.01) within 10 to 90 minutes. Hematoma expansion more than 40% of its volume occurred significantly less in the 4F-PCC group (4F-PCC group 0% vs. FFP group 24.2%, p=0.015). The number of cases with mRS 5 or 6 at discharge were nonsignificantly smaller in the 4F-PCC group (12.5% vs. 33.3%, p=0.11). Two cerebral embolisms (8%) were noted in the PCC group within 4 days after 4F-PCC administration.

Clinical course of warfarin associated intracerebral hemorrhage reversed by PCC or FFP

	PCC group (n=24)	FFP group (n=33)	p value
hematoma expansion more than 1.4-fold	0%	24%(8)	0.015
emergent surgery because of hematoma expansion	0%	15%(5)	0.06
mRS 5 or 6 at discharge	12%(3)	33%(11)	0.11
thromboembolic event	8%(2)	0%	0.17

Discussion

To prevent hematoma expansion in warfarin associated ICH, rapid correction of coagulopathy with 4F-PCC was efficient. On the other hand, two thromboembolic adverse events were observed in our series 3 days and 4 days after 4F-PCC administration, respectively. It is reported that, in warfarin associated ICH, hematoma expands for 24 hours especially with PT-INR value of >2.0. So we recommend that anticoagulants should be resumed 24 hours after immediate correction of PT-INR with 4F-PCC administration if hematoma remained unchanged.

Conclusions

Hematoma expansion was significantly less in the 4F-PCC group and that might be associated with better prognosis in the patients with warfarin-associated ICH. However, adverse effects such as subsequent cerebral embolism should be monitored carefully.

Learning Objectives

By the conclusion of this session, participants should be able to describe the importance of 4F-PCC for the patients with warfarin-induced ICH.