CNS 2017 ANNUAL MEETING
BOSTON, MASSACHUSETTS
OCTOBER 7–11, 2017

The Technique Modification for Deep Brain Stimulation Extension Lead Tunneling to Address "Bowstringing"

Viktoras Palys MD; Jamie Toms MD; Kathryn L. Holloway MD
Virginia Commonwealth University

Introduction

DBS hardware longevity and patient satisfaction in large part rely on the technical details of the extracranial parts of the DBS surgery. One of the cosmetic and comfort issues relates to *bowstringing* or *wire tethering* – an unsightly long tense subcutaneous cord where the DBS extension leads course through the neck subcutaneous tissue. The published incidence of *bowstringing* varies from 0.6% to 6.7%. In our experience, it becomes apparent at 4-6 weeks postoperatively and worsens with the maturation of the scar tissue. In extreme cases, neck rotation causes movement of the implanted pulse generator (IPG) as well as tension and discomfort sufficient enough to consider scar revision surgery. Tunneling of the DBS extensions deep enough to prevent adhesion to the subdermal area and immediate postoperative range of neck motion exercises seem to lessen the development of this complication, nonetheless, *bowstringing* remains a risk where two DBS extensions travel side-by-side in a single subcutaneous tunnel. On the other hand, we observed that it is rarely an issue with a single DBS extension. This fact led us to a modification of the technique so that each DBS extension has its own tunnel in the lower neck. We postulate that such path separation redistributes tension forces, thus, preventing unidirectional scar contraction and tethering.

Methods

During the second stage of DBS surgery, the DBS extension leads are tunneled subcutaneously from the scalp incision towards the infraclavicular incision for the IPG. We intentionally make one interim skin incision at the mastoid process level. From there the two DBS extension leads take a divergent course and then converge back at the IPG site.

Results

Since the introduction of divergent DBS extension lead tunneling in April 2016, with 24 patients who underwent double DBS lead implantations, we have seen significantly improved cosmetic effects in the neck.

Conclusions

The simple adjustment of the DBS extension lead tunneling technique augments cosmesis and patient satisfaction. Nonetheless, for the high risk cases, such as patients with a very thin neck or cervical dystonia, one may consider bilateral tunneling of DBS extension leads to two independent single-channel IPGs.

Learning Objectives

By the conclusion of this session, participants should be able to: 1) Describe the techniques for DBS extensions lead tunneling; 2) Discuss, in small groups, complications of DBS extensions lead tunneling; 3) Identify the strengths and drawbacks of different DBS extensions lead tunneling techniques.

Surgical technique

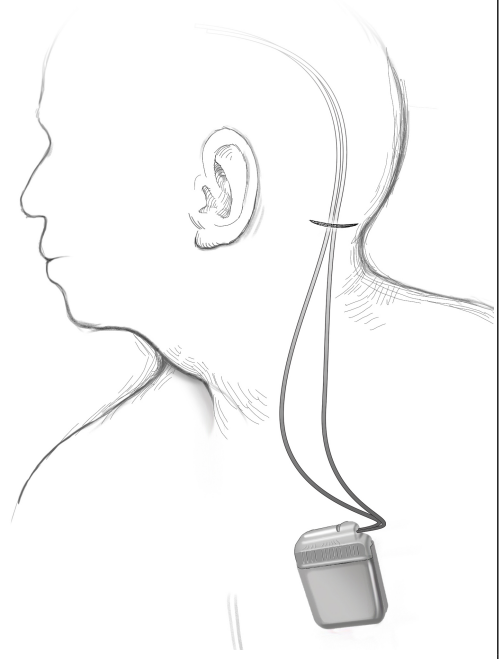

Divergent tunneling technique for DBS extension leads.

References

1. Falowski S, Ooi YC, Smith A, Verhargen Metman L, Bakay RAE: An evaluation of hardware and surgical complications with deep brain stimulation based on diagnosis and lead location. Stereotact Funct Neurosurg 2012; 90: 173–180.
2. Janson C, Maxwell R, Gupte AA, Abosch A: Bowstringing as a complication of deep brain stimulation. Neurosurgery 2010; 66:E1205
3. Miller PM, Gross RE: Wire tethering or 'bowstringing' as a long-term hardware-related complication of deep brain stimulation. Stereotact Funct Neurosurg 2009; 87: 353–359
4. Akram H, Limousin P, Hyam J, Hariz MI, Zrinzo L: Aim for the Suprasternal Notch: Technical Note to Avoid Bowstringing after Deep Brain Stimulation. Stereotact Funct Neurosurg 2015;93:227–230

Bowstringing

The examples of "bowstringing".

Dual tunneling

Postoperative results of divergent tunneling technique.