Thoracolumbar Spinal Subependymomas

Terry K. Schiefer MD; Colten D. Bracken BS; Jeffrey T. Jacob MD; William E. Krauss MD; Mark A. Pichelmann MD; Michelle J. Clarke MD

Mayo Clinic, Department of Neurologic Surgery, Rochester, MN, USA

Introduction & Methods

Thoracolumbar intramedullary spinal subependymomas are extremely rare spinal cord tumors with only 6 cases being reported in the pertinent literature to date (1). We report our retrospective review of 3 consecutive cases of pathologically confirmed thoracolumbar spinal subependymomas surgically treated at our institution between 1995 and 2008, comprising the largest single series of this entity to date.

Results

All three patients in our series were females, aged 22 (Patient A), 53 (Patient B), and 68 (Patient C) at the time of presentation. Each presented with both motor and sensory symptoms and Patient B had evidence of bladder dysfunction. On MRI all three of the tumors were hypo- to isointense on T1-weighted imaging and hyperintense on T2-weighted imaging. There were small areas of enhancment in both Patient A and B, but not in Patient C. Gross total resection (GTR) was performed in Patient A and resulted in complete loss of spinal cord function below the level of the surgery. Patient B underwent subtotal resection (STR) and was transiently worse after the surgery but improved. Patient C underwent biopsy and duraplasty only and was unchanged postoperatively. Mean duration of follow up with serial imaging was 8.1 years (range 2.4 to 16 years). Despite GTR, Patient A had radiographic evidence of tumor recurrence after 10 years. The recurrent tumor progressed and caused severe thoracic radicular pain prompting resection 15 years after the original surgery. Serial imaging in Patient B demonstrated progressive growth of the remaining tumor. There was no significant change in the tumor in Patient C during limited follow up. No patient received any adjuvant therapy.

Patient A, 15 Years Post-op

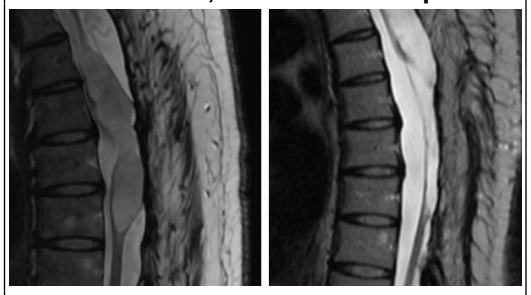

Left: Sagittal T2-weighted MRI shows recurrent tumor after GTR. Right: Post-op sagittal T2-weighted MRI s/p resection of recurrent tumor.

Patient B, Initial Scan

Left: Sagittal T2-weighted MRI of tumor prior to resection. Right: Sagittal T1-weighted MRI w/gad shows some areas of enhancement.

Patient B, 1 Year Post-op

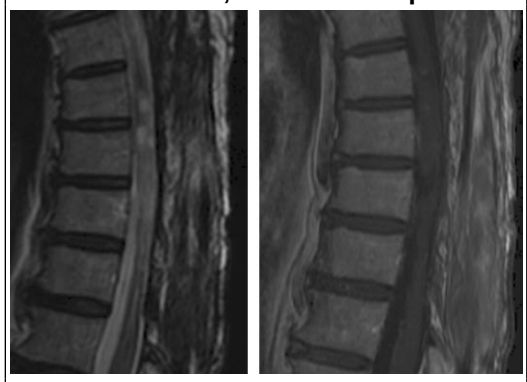

Left: Sagittal T2-weighted MRI demonstrates small amount of residual tumor superiorly. Right: Sagittal T1-weighted MRI with gadolinium shows no enhancment in this region.

Patient B, 6 Years Post-op

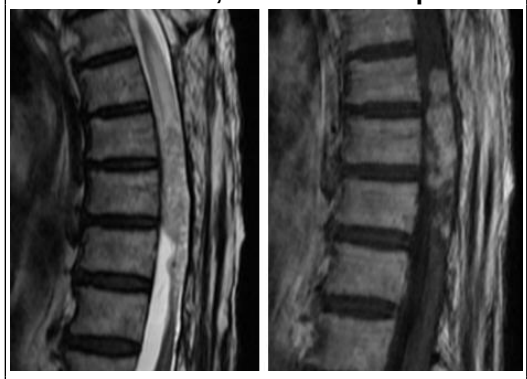

Left: Sagittal T2-weighted MRI shows significant tumor growth. Right: Sagittal T1-weighted MRI with gadolinium shows new enhancement in the region of tumor growth.

Discussion

Only six of these rare tumors have been reported to date (1), with these three cases making nine total in the current English literature. Presentation is similar to other intramedullary tumors and they appear hyperintense on T2-weighted MRI and hypo- to isointense on T1-weighted MRI. In the previously reported six cases, there was no gadolium enhancement. However, two of our cases enhanced with contrast. While these tumors may be amenable to GTR with minimal neurological sequelae, this is not always the case. Our patient that underwent GTR had loss of both sensory and motor function below the level of surgery and another patient's tumor was not amenable to GTR. Furthermore, while no recurrences have been reported in the previous six cases, the patient in our series that underwent GTR recurred 10 years after resection. Furthermore, the patient that undewent subtotal resection had progressive growth of the remaining tumor after several years. Thus, even after GTR, these tumors require vigilant radiographic follow up.

Conclusions

We add our experience of thoracolumbar subependymomas to the literature. While no other recurrences have been reported, our experience suggests that prolonged imaging follow up is necessary in these patients, even after GTR.

References

1.Orakcioglu B, Schramm P, Kohlhof P, Aschoff A, Unterberg A, Halatsch M-E. Characteristics of thoracolumbar intramedullary subependymomas. Journal of neurosurgery Spine 2009;10:54-9.