

Introduction

Spinal cord injury (SCI) is a devastating event that adversely impacts its victims. Numerous surgical and medical attempts have been made to improve the outcomes with varying degrees of success. The INSPIRE Study (InVivo Therapeutics Holding Corporation, Cambridge, Massachusetts, USA) is a prospective clinical trial on the use of bioengineered scaffolds implanted into the spinal cords of ASIA A SCI victims within 96 hours of the index injury event. Following the acute SCI, a biodegradable polymer Neural-Spinal Scaffold is surgically implanted into the patient's spinal cord.

Prior to the surgery, all patients undergo MR imaging. The results of the imaging studies and the findings at the time of surgery have differed. The purpose of this review was to compare the radiographic appearances with the gross appearances of the spinal cord at the time of surgery.

Methods

Patients with thoracic ASIA A SCI are eligible for enrollment in the INSPIRE Study. Exclusion criteria included penetrating injuries and anatomical transections. Surgeries must be completed within 96 hours. In the first 5 patients enrolled, all underwent MR imaging studies. In all cases, surgery was performed using high-resolution operating microscopes. Photomicrographs were compared with MR imaging. Clinical results of the INSPIRE Study are still pending as the study is ongoing.

Results

This report describes the first 5 patients enrolled in the INSPIRE Study. These patients were operated upon at 4 different US study sites. All patients had blunt, thoracic ASIA A SCI and had MR performed. Surgery was performed at a mean of 51.9 hours from the injury. In each case, the MR demonstrated abnormal signal in the substance of the spinal cord. These abnormal regions were consistent with either hemorrhage or contusion. In none of these MRs was a cavity visualized in the spinal cord. Varying degrees of fractures with subluxations were evident in all cases.

At the time of surgery, laminectomies were performed. In each of the cases, a well-defined cavity was identified in the spinal cord parenchyma. The intradural surgery was performed using high-resolution operating microscopes. Two distinct patterns were identified. A "contusion" injury involved injuries where the peripheral white matter of the spinal cord appeared to be intact while necrotic/hemorrhagic tissue was present in the central part of the cord parenchyma. A "compound" injury was detected when elements of contusion, laceration, and maceration were all present and the peripheral white matter was damaged.

In the 3 contusion-type injuries, a midline myelotomy was performed. In each, necrotic and hemorrhagic material expressed itself through the

myelotomy. After microirrigation with saline, a well-formed cavity was evident in the central portion of the spinal cord. The scaffold was inserted into this cavity.

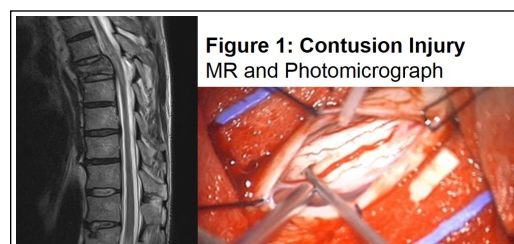


Figure 1: Contusion Injury
MR and Photomicrograph

In the 2 compound-type injuries, the white matter was clearly violated and a cavity was evident extending from this point into the spinal cord. Again, following microirrigation of the cavity, a scaffold was placed with the cavity. As each of these cases involved unstable fracture-subluxations to varying degrees, internal fixation with spinal instrumentation/fusion was performed.

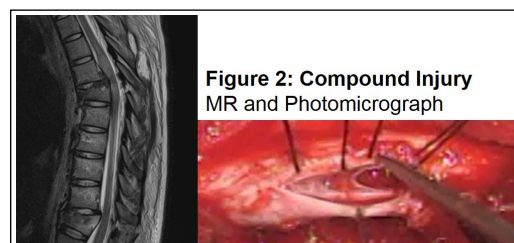


Figure 2: Compound Injury
MR and Photomicrograph

After the operative findings were determined, a separate neuroradiologist retrospectively analyzed each case. Despite knowledge that a cavity was present, this review failed to demonstrate MR findings consistent with the presence of a cavity. All patients continue to be followed as part of the INSPIRE Study. The clinical and radiographic findings will be reported at a later date.

Discussion

The appearance of cavities or cysts in the spinal cord following blunt traumatic injuries is well known. These cavities are typically identified in the chronic stages following a traumatic SCI.

The presence of an acute cavity is not reported in the medical literature describing SCI. The likely reason for this is that spine surgeons go to great lengths to avoid opening the dura. As such, it is conceivable that a spinal cord cavity is present in a percentage of severely traumatized spinal cords. Review of the radiology literature on the MR imaging appearances of the spinal cord following acute SCI does not identify the presence of cavities. Hemorrhages and contusions are routinely identified. It is likely that there is appreciable pressure on the spinal cord parenchyma at the time of the initial MR and this may be the reason why the presence of a discrete cavity, clearly seen at the time of surgery in all 5 cases, was not visualized.

This study makes clear multiple findings that have not been previously reported. Following acute thoracic ASIA A SCI, a cavity is routinely present within the spinal cord. Likewise, MR imaging following severe, acute SCI is not able to identify the presence of a cavity. At present, it is clear that MR imaging is unable to identify cavities which are routinely visualized at the time of surgery for acute, traumatic thoracic SCI patients.